

^{99m}Tc MDP and ^{67}Ga Gallium Dual Isotope Imaging in the Evaluation of Sternal Osteomyelitis and Wound Dehiscence

Shanmuga Sundaram Palaniswamy* and Padma Subramanyam

Department of Nuclear medicine & PETCT, Amrita Institute of medical sciences, Cochin -41, Kerala, India

*Corresponding author: Shanmuga Sundaram Palaniswamy, Head, Department of Nuclear medicine & PETCT, Amrita Institute of medical sciences, Cochin -41, Kerala, India, Tel: 91-484-2852001; Fax: 91-484-2852003; E-mail: ssundaram@aims.amrita.edu

Received date: Sep 03, 2015, Accepted date: Nov 10, 2015, Publication date: Nov 16, 2015

Copyright: © 2015 Sundaram SP, et al. This is an open-access article distributed under the terms of the Creative Commons Attribution License; which permits unrestricted use; distribution; and reproduction in any medium; provided the original author and source are credited.

Abstract

Sternal infections are a major cause of morbidity and mortality in patients undergoing cardiac surgery. They occur in 1% to 3% of patients who undergo open-heart surgery and carry a moderately high mortality rate. Sternal infections can range from minor, superficial infections to open mediastinitis with invasion of the sternum, heart, and great vessels. Infection can lead to partial or complete separation of bony sternum thus compounding the problem. Identifying osteomyelitis (OM) is a challenge to the surgeons especially in the postoperative setting. Although clinically presence of fever and leukocytosis along with sternal wound dehiscence suggests deep infection. Localization and ascertaining the extent of sternal infection is difficult. Treatment entails surgical debridement with closed irrigation, open-wound packing, or muscle or omental flap procedures, as well as antibiotic therapy. In sternal OM, delineation of sinus tracts into the various planes of anterior mediastinal tissues is essential to achieve proper surgical drainage and antibiotic cover. This is exclusively achieved by Gallium infection imaging and additional use of SPECTCT (Single photon emission computed tomography). Only when the postoperative site is devoid of residual infection, thoracic and trunk reconstruction can be performed to provide stability to sternal dehiscence.

Keywords: ^{99m}Tc MDP bone scan; ^{67}Ga Gallium infection imaging; Sternal osteomyelitis; Wound dehiscence

radical debridements or Vacuum assisted closure [5], flap cover and enhance healing.

Introduction

Median Sternotomy is the choice of access for most major cardiac surgeries. An uncommon complication of this access route is sternal infection and sternotomy wound dehiscence with an incidence of 0.2% to 10 % in literature [1]. This is a serious condition with a high mortality sometimes as high as 50% especially if associated with mediastinitis [2,3]. Risk factors for sternal wound dehiscence due to deep infections include diabetes, obesity, chronic obstructive pulmonary disease, osteoporosis, tobacco use, reoperation, prolonged intensive care unit stays, and use of assist devices. Successful treatment of sternotomy osteomyelitis (OM) and wound dehiscence needs stable soft tissue cover with a rigid fixation of the sternum after achieving a healthy wound environment [4]. Early thorough debridement of infected and devitalised tissue is essential to achieve this goal [5].

In some cases however, it is difficult to assess the complete extent of chronic infective foci either clinically or even radiologically and inadequate debridement may result in failure to achieve a stable cover. ^{99m}Tc Methylene diphosphonate (MDP) bone scan is a time tested imaging modality in the assessment of suspected OM. However its use in post surgical setting for diagnosing OM is challenging and is found to be less sensitive. In this setting, additional imaging with ^{67}Ga Gallium citrate or ^{99m}Tc HMPAO labelled WBC (white blood cells) scan is useful to identify active infection [6,7].

When combined with SPECTCT (Single photon emission computed tomography), this combined imaging delineates the site and also the extent of bone and surrounding soft tissue infection. Thus bone and Gallium imaging serve as a guide to identify the pockets of occult infection in and around sternotomy wounds and help in performing

Materials and Methods

This was a retrospective study of 52 patients (Male: Female=42: 10, mean age 61 years), who were referred to our department between January 2011 and December 2013 for suspected OM.

All patients had undergone median sternotomy for a Coronary Artery Bypass Surgery. 23 out of 52 (44%) had already suffered one or more episodes of osteomyelitis previously OM. 39 out of 52 patients were diabetics on oral hypoglycemic agents. Patient selection criteria prior to nuclear imaging were based on one of the following;

1. Inability to control infections by appropriate antibiotics, repeated debridements, negative suction wound therapy.
2. Patients with recurrence of infection and wound dehiscence after previously closed sternal dehiscence wound by flap cover.

Imaging Protocol

Three phase regional bone scan

^{99m}Tc MDP was administered intravenously (antecubital vein) at a dose of 15 millicurie (mCi). Immediate dynamic (vascular phase) anterior thorax images (128 × 128 matrix; 2 sec/frame) were acquired for 60 seconds followed by soft tissue phase static images (256 × 256 matrix; 500 kilo counts). 3 hours later the skeletal phase images (anterior and posterior thorax) were acquired using a dual head variable angle Gamma camera. SPECTCT images of thorax were acquired at 25 sec/frame for 360° in 64 × 64 matrix.

Gallium scan

2 mCi of Gallium citrate was injected intravenously after completion of bone scan in all patients. Static images of anterior and posterior thorax were obtained 48 hours post injection after changing the window settings to gallium photo peak. Planar anterior and posterior views of thorax were acquired using Dual head variable angle Gamma Camera using high energy collimators.

All patients underwent Gallium SPECT CT imaging following the planar scans. Delayed images were acquired at 72 or 96 hours post injection in those patients with poor background tracer clearance for better delineation of infective focus or sinus tracts.

SPECTCT acquisition parameters are; 64 × 64 matrix at 40 seconds/frame for 360°. Image interpretation was performed by 2 blinded senior nuclear medicine consultants with over 10 years experience.

All patients underwent further debridements as guided by the imaging reports and were managed with appropriate antibiotics, negative suction wound therapy. After achieving good wound control they underwent flap cover for wound closure.

Results

Of the 52 patients imaged (Male : Female=42 : 10), 47 patients revealed localized OM i.e infection confined only around sternum with no surrounding soft tissue infection or sinus tract into muscular plane (combined bone and gallium imaging). Gallium SPECT CT and wound culture / sternal bone biopsies were used as end points in all these patients.

Interpretational criteria

In general, for diagnosing osteomyelitis, ⁶⁷Ga images are interpreted together with ^{99m}Tc MDP bone scans according to the following criteria:

a. The combined bone/gallium study is said to be negative for infection when (1) gallium scintigraphy is negative, regardless of the bone scintigraphy results; or (2) the distribution of MDP and Gallium on both studies is spatially congruent and the relative intensity of gallium activity is less than that of bone activity.

b. The combined bone/gallium study is positive for infection when (1) the distribution of activity on both studies is spatially congruent and the relative intensity of gallium activity is greater than that of bone uptake; or (2) the distribution of MDP and Gallium on both studies is spatially incongruent, with gallium activity exceeding bone activity in at least one site.

c. The combined bone/gallium study is equivocal for infection when the distribution of activity on both studies is spatially congruent and the relative intensity of the gallium activity is equal to the bone activity. This result can occur in patients who are taking antibiotics and are partially treated.

Gallium is also useful in identifying non-osseous sites of infection/inflammation (e.g., sinusitis, intra-abdominal abscess, joint sepsis, infected renal or hepatic cysts, etc.).

5 out of 52 patients with sternal wound dehiscence revealed active infection at sites distant from the sternum on combined imaging;

Patient 1: Bone scan revealed increased tracer uptake in manubrium sternum in skeletal phase alone with no corresponding gallium uptake.

Bone scan wise sternum had no active or smouldering osteomyelitis. However gallium images revealed substernal soft tissue focal increased gallium uptake at the level of 2nd rib suggesting surrounding soft tissue infection i.e mediastinitis.

Patient 2: Chronic active soft tissue infection in left anterior chest wall adjacent to the lower part of body of sternum, tracking down bilaterally into anterior chest wall and abdominal wall upto level of 12th rib on left side and 10th rib on right side.

Patient 3: Active chronic osteomyelitis of sternum with surrounding soft tissue inflammation extending to subcutaneous planes of lower anterior ribs bilaterally.

Patient 4: Active infection involving sternum and lower anterior costochondral junctions and 5th ribs bilaterally (Figure 1).

Patient 5: Active sternal OM with extension into the left 7th and 8th sternocostal region and tracking down into medial end of left 8th rib (Figure 2).

All these 5 patients were classified as type 3 sternal dehiscence wounds according to Pairolero and Arnold's classification of infected sternotomy wounds [8]. Localization of occult pockets of infection by combined bone/gallium SPECTCT imaging post sternotomy, guides the areas that need thorough debridement. In our series of patients the wounds healed after flap cover or primary closure once the healthy wound environment was achieved.

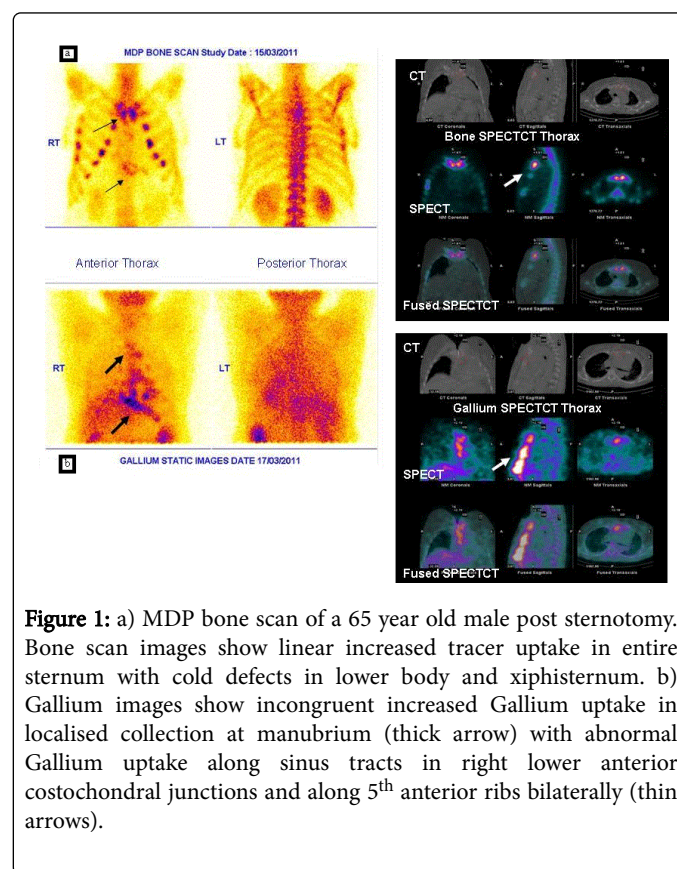


Figure 1: a) MDP bone scan of a 65 year old male post sternotomy. Bone scan images show linear increased tracer uptake in entire sternum with cold defects in lower body and xiphisternum. b) Gallium images show incongruent increased Gallium uptake in localised collection at manubrium (thick arrow) with abnormal Gallium uptake along sinus tracts in right lower anterior costochondral junctions and along 5th anterior ribs bilaterally (thin arrows).

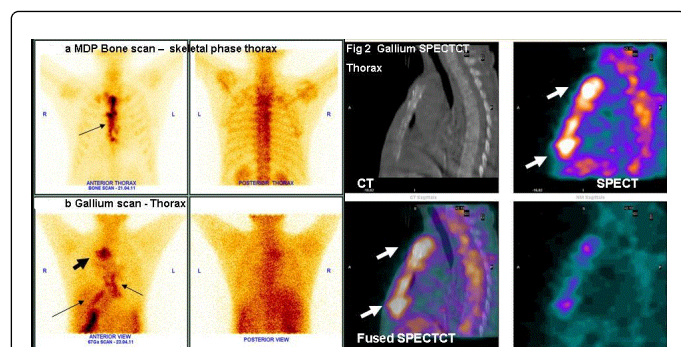


Figure 2: a) - Bone scan images of a 56 yr old female post sternotomy show a) increased tracer uptake in manubrium sternum corresponding to the site of surgical intervention b) Increased tracer uptake in lower sternal region with cold defect. c) Hot spots in left 7th, 8th sternocostal joint region extending along the left 8th rib. b) Focal hot spots seen in multiple bilateral costochondral junctions – suggesting costochondritis. b) Gallium scan images of the same patient show incongruent linear increased gallium uptake extending from posterior aspect of manubrium sternum to lower end of sternum. There is abnormal focal gallium uptake in left 7th and 8th costosternal region with extension along the medial end of left 8th rib. Findings are suggestive of sternal OM with multiple pockets of soft tissue infection in anterior mediastinum.

Discussion

Generally OM can be classified by duration (acute or chronic), pathogenesis (trauma, contiguous spread, hematogenous, surgical), site, extent, or type of patient. Although several classifications of OM have been described in literature, the two most widely used in clinical practice are the classification systems by Waldvogel et al. [9] and Cierny et al. [10] Under the Waldvogel system, osteomyelitis is first described according to duration, either acute or chronic. Second, the disease is classified according to source of infection, as hematogenous when it originates from a bacteremia or as contiguous focus when it originates from adjacent ongoing soft tissue infection. The Cierny-Mader classification is a clinical classification based on anatomic, clinical, and radiologic features. Usually it is thought that bacteria causing OM persist within glycocalyx-enclosed microcolonies adherent to the bone and to prosthetic devices rendering them refractory to standard treatment.

Mechanisms proposed to explain the development of sternal wound infection and dehiscence include inadequate sternal fixation leading to instability and dehiscence of the overlying skin incision and inadequate surgical drainage. Further theories suggest a localized ischemia or loosening of sternal wires leading to sternal instability, which ultimately leads to skin dehiscence and osteomyelitis. Staphylococcus aureus in the most commonly cultured organism.

Pairlero and Arnold have classified sternal wound dehiscence into 3 types [8].

Type 1: Occurs within first few days and presents with serosanguineous drainage. Cellulitis is absent and mediastinum is soft and pliable. Osteomyelitis and costochondritis are absent and cultures are usually negative.

Type 2: Occurs within first few weeks and presents with purulent drainage. Cellulitis is present with mediastinal suppuration. Osteomyelitis is frequent although costochondritis is rare. Cultures are invariably positive.

Type 3: Occurs months to years after sternotomy and presents with chronic draining sinus/sinuses. Cellulitis is localized and mediastinitis is rare. Osteomyelitis, costochondritis or a retained foreign body is always present. Cultures are positive.

It is widely accepted that complete and radical debridement is essential to gain a healthy wound environment before giving a soft tissue cover for type 2 and 3 wounds [4,5]. If the initial attempt at debridement, coverage, and closure fails and infection recurs, the usual primary cause is retained sequestrum and inadequate debridement at the first attempt [5]. To assess clinically the true extent of chronically infected tissue is difficult. Nuclear techniques combining bone/gallium or Indium WBC is an invaluable tool for uncovering the underlying infective pathology [6].

Although routine investigations like hematological tests, plain radiographs (anteroposterior [AP] or posteroanterior [PA]), ultrasonography and computed tomography are available they are unreliable to detect focus of infection especially at sites distant from the sternum. Radiographs may detect air in the mediastinum; a sternal stripe reflects air between separated sternal halves. CT can accurately detect sternal disruption, pockets of fluid, abscess, or pleural effusions.

Bone scan is falsely positive in patients undergoing any type of surgical intervention and cannot reliably indicate the presence of co existing infection. Additional imaging with ^{99m}Tc labelled WBC or gallium is essential in such clinical setting. Although Tc WBC imaging as a sole imaging technique for localising infection is established; labelling is tough, needs expertise, time consuming, involves direct handling of blood products, and the cold kit is expensive and not universally available. Combined Gallium and bone scan is preferred as the imaging modality of choice in identifying osteomyelitis [7]. Gallium is the tracer of choice for identifying chronic infective foci rather than acute cases [7]. It has been used for detecting spinal osteomyelitis [11-13] and for sternal osteomyelitis [14,15]. It has atomic structure and biological activity similar to iron. It circulates in the blood stream bound to plasma transferrin. Sites of inflammation have higher concentrations of iron binding compounds viz. lactoferrin (which is secreted by neutrophils) and siderophores (which are secreted by bacteria). Since ⁶⁷Ga has higher affinity for lactoferrin and siderophores than transferrin, it binds to these two and localizes to the site of inflammation [11]. It has a physical half life of 78 hours. In the first 24 hours 10-25% of the total injected dose is excreted by kidneys, after which the principal site of excretion is the gastrointestinal tract. By 48 hours Gallium Citrate gets equally distributed among liver, bone and soft tissues and is maximally concentrated at sites of on going inflammation [11,12]. The society for nuclear medicine has published guidelines for interpretation of gallium scintigraphy in conditions of inflammation [11].

In our series of 52 patients of sternotomy dehiscence we had 5 patients of type 3 sternal wound dehiscence whose true extent of infected tissue could not be assessed clinically. This resulted in suboptimal debridements and failure to achieve a healthy wound. Bone and Gallium scan proved that presence of residual bone or soft tissue infection lead to recurrence of OM. Addition of SPECT CT gave a 3 dimensional information of the extent and the tracking of sinuses in soft tissue and muscle planes of anterior mediastinum. Thus it is

essential to achieve propersurgical drainage and antibiotic cover prior to flap reconstruction to provide stability especially in patients with sternal dehiscence [16].

Conclusion

Skeletal scintigraphy and Gallium scan in combination with SPECT CT can be a useful investigative modality to detect occult infection in post sternotomy settings with mediastinitis especially in areas such as the substernal mediastinum, ribs, costal cartilages and soft tissues of the anterior chest wall.

References

1. Landes G, Harris PG, Sampalis JS, Brutus JP, Cordoba C, et al. (2007) Outcomes in the management of sternal dehiscence by plastic surgery: a ten-year review in one university center. *Ann Plast Surg* 59: 659-666.
2. Ridderstolpe L, Gill H, Granfeldt H, Ahlfeldt H, Rutberg H (2001) Superficial and deep sternal wound complications: incidence, risk factors and mortality. *Eur J Cardiothorac Surg* 20: 1168-1175.
3. de Feo M, de Santo L, Romano G, Renzulli A, della Corte A, et al. (2003) Treatment of recurrent staphylococcal mediastinitis: Still a controversial issue. *Ann Thorac Surg* 75: 538-542.
4. Fawzy H, Osei-Tutu K, Errett L, Latter D, Bonneau D, et al. (2011) Sternal plate fixation for sternal wound reconstruction: initial experience (retrospective study). *J Cardiothorac Surg* 6: 63.
5. Song DH, Wu LC, Lohman RF, Gottlieb LJ, Franczyk M (2003) Vacuum assisted closure for the treatment of sternal wounds: the bridge between debridement and definitive closure. *Plast Reconstr Surg* 111: 92-97.
6. Quirce R, Carril JM, Gutiérrez-Mendiguchía C, Serrano J, Rabasa JM, et al. (2002) Assessment of the diagnostic capacity of planar scintigraphy and SPECT with ^{99m}Tc-HMPAO-labelled leukocytes in superficial and deep sternal infections after median sternotomy. *Nucl Med Commun* 23: 453-459.
7. Staab EV, McCartney WH (1978) Role of gallium 67 in inflammatory disease. *Semin Nucl Med* 8: 219-234.
8. Pairolo PC, Arnold PG (1985) Chest wall tumors. Experience with 100 consecutive patients. *J Thorac Cardiovasc Surg* 90: 367-372.
9. Waldvogel FA, Medoff G, Swartz MN (1970) Osteomyelitis: a review of clinical features, therapeutic considerations and unusual aspects. *N Engl J Med* 282: 316-322.
10. Cierny G 3rd, Mader JT, Penninck JJ (2003) A clinical staging system for adult osteomyelitis. *Clin Orthop Relat Res* : 7-24.
11. Seabold JE, Palestro CJ, Brown ML, Datz FL, Forstrom LA, et al. (1997) Procedure guidelines for gallium scintigraphy in inflammation. *J Nucl Med* 38: 994e997.
12. Love C, Patel M, Lonner BS, Tomas MB, Palestro CJ (2000) Diagnosing spinal osteomyelitis: a comparison of bone and Ga-67 scintigraphy and magnetic resonance imaging. *Clin Nucl Med* 25: 963-977.
13. Haase D, Martin R, Marrie T (1980) Radionuclide imaging in pyogenic vertebral osteomyelitis. *Clin Nucl Med* 5: 533-537.
14. Elgazzar AH (1997) Imaging of infection: a correlative and algorithmic approach. *J Family Community Med* 4: 21-31.
15. Salit IE, Detsky AS, Simor AE, Weisel RD, Feiglin D (1983) Gallium-67 scanning in the diagnosis of postoperative sternal osteomyelitis: concise communication. *J Nucl Med* 24: 1001-1004.
16. Singh K, Anderson E, Harper JG (2011) Overview and management of sternal wound infection. *Semin Plast Surg* 25: 25-33.