

Case Report

Open Access

# A Case of Syncope with Elevated C-Peptide Levels in a 22-Year Old Male: A Case Report

Thomas Diver and Long Wong\*

Department of Family Medicine, Texas College of Osteopathic Medicine, University of North Texas Health Science Center, Fort Worth, USA

## Abstract

There are multiple causes of syncope, which is a short loss of consciousness and muscle strength, characterized by a fast onset, short duration, and spontaneous recovery. The exactly cause of syncope in young adult is usually difficult to figure out. This case report describes syncope in a young adult with multiple intermittent high C-peptide levels upon testing.

**Keywords:** Syncope; Muscle strength; Down's syndrome

## Case Report

A 22 year old white male with Down's syndrome presented to a family medicine clinic with increased intermittent episodes of syncope. These episodes lasted approximately 3-5 minutes and the patient awoke without recall. The patient presented with two main complaints, seizures and syncope frequently over the last two years. The syncope and seizure occurs simultaneously (Figure 1). The seizures were consistent with epilepsy and he was given Keppra 750 milligrams an anti-convulsant that controlled these symptoms initially. However, the syncope episode came back again. Laboratory evaluations showed an elevated C-Peptide 3.25 to 12.20 ng/mL over the last two years (0.8-3.1 normal range) with each episode of syncope, Insulin level 9 uIU/mL (<23 normal range), Insulin autoantibody <0.4 U/mL (<0.4 normal range), hemoglobin A1c 5.7 (<5.7 normal range), Prolactin levels 5.0 ng/mL (2.0-18.0 normal range), Calcium 9.6 mg/dL (8.6-10.3 normal range), Parathyroid hormone, Intact 24 pg/mL (14-64 normal range) and his CBC and CMP were also within normal range. The cardiology evaluation was unremarkable.

In detail the Syncope is multifactorial and requires a broad approach to diagnosis which involves taking an in depth history, reviewing medications, a thorough physical exam, blood pressure measurement, electrocardiogram and neurological exam. A syncope protocol was used to determine if hospitalization is required. Further testing was done due to the etiology being unclear. Cardiology evaluation revealed a systolic ejection murmur II/VI and normal LV systolic function with no significant valvular abnormalities by prior Transthoracic Echocardiogram (TTE) Electrocardiogram shows a normal sinus rhythm, his heart rate was 79 beats per minute and RSR in V1. Magnetic Resonance imaging (MRI) of the brain in multiple planes was performed. The study demonstrated no evidence of mass or mass-effect (Figure 2). The ventricular system is normal and there is no

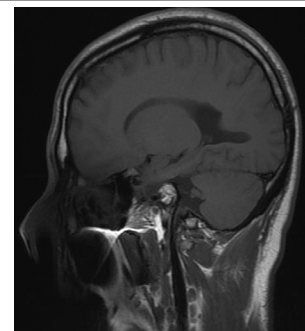
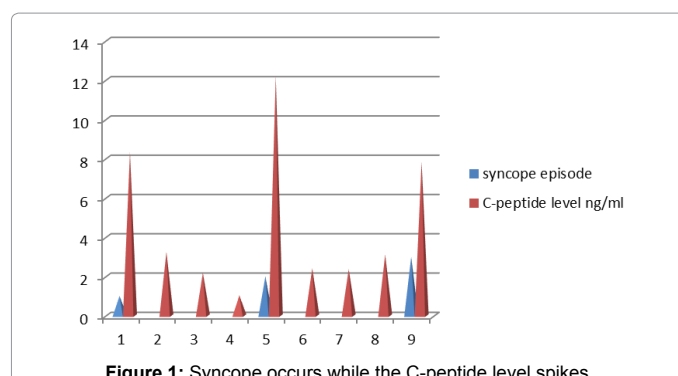


Figure 2: The result of Brain MRI was negative.

evidence of extra-axial fluid. There are no areas of abnormally increased or decreased signal intensity nor any abnormally enhancing lesions that were identified. The midline structures are unremarkable ruling out neurological causes. Computed Tomography (CT) of the abdomen with and without contrast was performed using 5mm helical images were made from the dome of the diaphragm to the aortic bifurcation following oral contrast administration. Resultant images were viewed on soft tissue window settings. The lung bases are clear. The liver, spleen, pancreas, gallbladder, adrenal glands and kidneys are unremarkable. There is no intra-abdominal or retroperitoneal adenopathy. Opacified bowel loops in the upper abdomen are unremarkable. There is no ascites. There is no evidence of an abdominal wall hernia revealing an unremarkable CT of the abdomen. C-Peptide measurements were elevated greater than 3.1 ng/mL (0.80-3.1 normal range) with each episode of syncope and normal laboratory levels of glucose, calcium, parathyroid hormone, insulin level, prolactin level and a complete blood count.

Insulin and C-Peptide are secreted in response to all insulin secretagogues. Although proinsulin may have some mild hypoglycemic action, C-peptide has no physiological function. Originally, the unit



\*Corresponding author: Long Wong, Department of Family Medicine, Texas College of Osteopathic Medicine, University of North Texas Health Science Center, Fort Worth, USA, Tel: +1 817-735-2000; E-mail: [Long.Wong@unthsc.edu](mailto:Long.Wong@unthsc.edu)

Received November 04, 2015; Accepted December 07, 2015; Published December 14, 2015

Citation: Diver T, Wong L (2015) A Case of Syncope with Elevated C-Peptide Levels in a 22-Year Old Male: A Case Report. J Clin Case Rep 5: 666. doi:10.4172/2165-7920.1000666

Copyright: © 2015 Diver T, et al. This is an open-access article distributed under the terms of the Creative Commons Attribution License, which permits unrestricted use, distribution, and reproduction in any medium, provided the original author and source are credited.

was defined on the basis of hypoglycemia activity of insulin in rabbits. With improved purification techniques C-peptide is presently defined on the basis of weight, and present insulin standards used for assay purposes contain 28 units per milligram.

## Discussion

22 years old male present with multiple episode syncope and seizure. The syncope and seizure occurs at the same time. It was really hard to distinguish those two from each other even that we carefully reviewed the patients' medical record from the Emergency Room and Hospitals. We also interviewed the patient and his parent multiple times. Patient denied use of any insulin or use of any other diabetic medications. The evaluation of this patient was unremarkable, the patient was continuously followed at our Family Medicine clinic by monitoring the patients' C-peptide levels. The result indicated syncope and seizures occurred while his C-peptide level continued to spike. MRI of patient brain was done which revealed a negative result. Based on the reference Harrison Principle of Internal Medicine an MRI can only detect 45-75% of insulinomas [1-3].

## Conclusion

The likely explanation for this case is that this patient has a possible

insulinoma, an insulin secreting tumor of the islets of Langerhans even with a negative Brain MRI and abdominal Computerized Tomography Scan. These tumors can appear at any age and generally have symptoms of episodic disorientation, somnolence, personality changes, amnesia and loss of consciousness due to the production of excessive insulin resulting with a hypoglycemia event. The hypoglycemia induced intracellular signal change, which eventually triggered these seizure episodes. This patients' syncope was due the combination of hypoglycemia and subsequent seizure due to a recurrent central nervous system dysfunction. This patients symptoms are still unresolved and has been referred to Endocrinology for further evaluation of his continued hypoglycemia, and elevated C-peptide levels for a probable insulinoma. Patient was also referral to neurology for management of his seizure disorder.

## References

1. Agrawal K, Young R, Dressler DD (2012) Syncope. *Principles and Practice of Hospital Medicine* In McKean SC, Ross JJ, Dressler DD, Brotman DJ, Ginsberg JS
2. Jensen RT (2012) Chapter 350. Endocrine tumors of the Gastrointestinal Tract and Pancreas. In Longo DL, Fauci, AS, Kasper DL, Hauser SL, Jameson J, Loscalzo J (Eds). *Harrison's Principles of Internal Medicine*.
3. Kennedy M, Masharani U (2015) Pancreatic Hormones & Antidiabetic Drugs. In: Katzung BG, Trevor AJ (Eds), *Basic & Clinical Pharmacology*, 13e.