

A Comparison of Three Dimensional Ultrasound, Clips and CT for Measuring Interfractional Breast Lumpectomy Cavity Motion

Ruth Heimann^{1*}, Daphne Hard¹, Jessica Archambault¹, Suzanne Gross¹ and Martin Lachaine²

¹Division of Radiation Oncology, Vermont Cancer Center, University of Vermont Medical Center, Burlington, VT, USA

²Elekta, Montreal, Quebec, Canada

*Corresponding author: Ruth Heimann, Division of Radiation Oncology, University of Vermont Medical Center, 111 Colchester Ave, USA, Tel: +1 802-847-0000; E-mail: ruth.heimann@uvmhealth.org

Received date: Dec 17, 2015, Accepted date: Feb 05, 2016, Publication date: Feb 12, 2016

Copyright: © 2016 Heimann R, et al. This is an open-access article distributed under the terms of the Creative Commons Attribution License; which permits unrestricted use; distribution in any medium; provided the original author and source are credited.

Abstract

Accurate definition of the lumpectomy cavity (LC) is essential for both partial breast and electron boost planning and delivery. The goal of this study is to evaluate CT, 3DUS and clips in the daily target localization of the LC. Twenty whole breast radiation patients, including 10 with clips, underwent two sets of treatment planning CTs (CT1, CT2) with co-registered 3DUS (US1, US2), separated by approximately 6 weeks. The cavities were independently outlined on each CT and 3DUS dataset. Of the 20 patients, 18 had visible cavities. The shifts in cavity position were calculated from CT, 3DUS and clips. The PTV margins required to be added to the CT1 cavity volume in order to fully encompass the CT2 cavity were calculated without and with shifts according to 3DUS or clips. The median cavity displacement ranged from 0.0-3.0 mm with a maximum of up to 17.9 mm. The cavity displacements were not significantly different when calculated based on 3DUS, CT, or clips ($p > 0.05$). The average PTV margin required to encompass the CT2 cavity was 6.3 mm without shifts, 4.3 mm with 3DUS shifts and 5.2 mm with clip-based shifts. The differences in the margin between no shift and 3DUS or clip-guided shift were found to be significant, while differences between 3DUS and clip-based shifts were not ($p > 0.7$). With no shift, the mean CT2 volume that lied outside the CT1 was 3.2 cc compared to 2.4 cc ($p < 0.03$) with 3DUS and 2.8 cc ($p < 0.05$) with clip-based shift. The volume difference between the shifting methods was not significant ($p > 0.9$). Without adjusting for the changes in the cavity shape and location, a portion of the volume will be undertreated unless the margins are increased. 3DUS may offer an easily implemented solution to localizing the LC without requiring additional ionizing radiation.

Keywords: Lumpectomy cavity; 3D ultrasound; Partial breast irradiation; Image guidance

Introduction

Accurate definition of the lumpectomy cavity is essential for both partial breast irradiation and electron boost planning and delivery. The radiation can be delivered to the partial breast either by brachytherapy or conformal external beam radiotherapy. The potential advantages of external beam partial breast irradiation (EB-PBI) are that it does not require an additional surgical procedure, the dose homogeneity within the target is superior, and it can be delivered in most radiotherapy departments [1]. A disadvantage, however, is that breast tissue is a mobile target, requiring additional margins to compensate for the motion.

Definition of the lumpectomy cavity itself has been shown to be prone to user-variability between physicians, in part due to the clarity of the seroma, and similar CT numbers for adjacent fibrosis, retroareolar tissue, and normal dense breast parenchyma [1-3]. The establishment of contouring guidelines has been shown to diminish this variability [4]. The NSABP B39 protocol [5] specifies an extra 1.5 cm cavity to clinical target volume (CTV) margin to account for residual disease. In addition, the protocol requires an extra CTV-to-PTV (planning target volume) margin of 1.0 cm to account for interfractional cavity motion, which can be caused by setup error, breast deformation, and changes in the cavity over time, as well as intrafractional breathing error.

The combination of cavity-to-CTV and CTV-to-PTV margins can lead to a large amount of irradiated tissue, which can both increase toxicity as well as reduce the number of patients eligible for the PBI technique. Weed et al. [6], by using clips to identify the cavity location, concluded that the CTV-to-PTV margin could be reduced from 1 cm to 0.5 cm using the clips for localization. Disadvantages of this method are that it uses additional ionizing radiation to non-target tissue such as the contra-lateral breast and lung, it requires the presence of clips that are not universally used, and it can be influenced by the potential migration of the clips [7].

A commercial 3D ultrasound (3DUS) breast system may allow the reduction of the volume of normal tissue needed for sufficient margins for EB-PBI by: a) defining the cavity for CTV using fused CT/3DUS images, and b) for imaging the cavity in the treatment room on a per-fraction basis. A study using this system has shown the usefulness of 3D ultrasound (3DUS), co-registered to the CT in defining the lumpectomy cavity [8]. The 3DUS improved user-variability demonstrating the potential usefulness of using fused CT/3DUS datasets for treatment planning in EB-PBI.

The goal of this study is to investigate the accuracy of comparing 3DUS images at time of treatment to 3DUS images at time of simulation to align the cavity relative to the treatment fields. This would allow accurate image-guided radiotherapy (IGRT) without using ionizing radiation and for patients with no surgical clips.

Materials and Methods

23 patients were enrolled in a prospective study at the Vermont Cancer Center between January 2007 and January 2008. The study was approved by the University of Vermont Institutional Review Board and in compliance with the Health Insurance Privacy and Portability Act. The patients enrolled in the study underwent whole breast irradiation with electron boost treatments.

3DUS system

3DUS images were acquired with the Clarity System (Elekta, Stockholm, Sweden). The system consists of 3DUS consoles in both the CT-Sim (US-Sim) and treatment room (US-Guide). US-Sim images share the same coordinate system as the CT images through a calibration process, and serve two purposes: a) fused CT/3DUS datasets for planning, and b) as a baseline reference images for image guided radiation therapy (IGRT). US-Guide images share the same coordinate system as the linear accelerator, i.e., they are centered about the isocenter. In clinical use, 3DUS images acquired prior to each treatment fraction can be compared to the reference US-Sim images, allowing an ultrasound-to-ultrasound comparison for IGRT. Ultrasound guidance in radiotherapy, including the Clarity System, has been summarized in a recent review article [9].

The breast US probe is linear and has frequencies in the range 5-12 MHz, with a central frequency of 9 MHz, allowing acquisition of images with a pixel resolution of 0.2 mm. The 3DUS images are reconstructed to a voxel size of 0.3 mm. Infrared reflecting markers are affixed to its handle, and are tracked in 3D space by an optical camera system. All images are sent through a central server to the Clarity Workstation, which allows fusion of CT and US data, contouring, and definition of the IGRT reference volume. An example 3DUS image acquired during this study is shown in Figure 1 in axial, sagittal and coronal views.

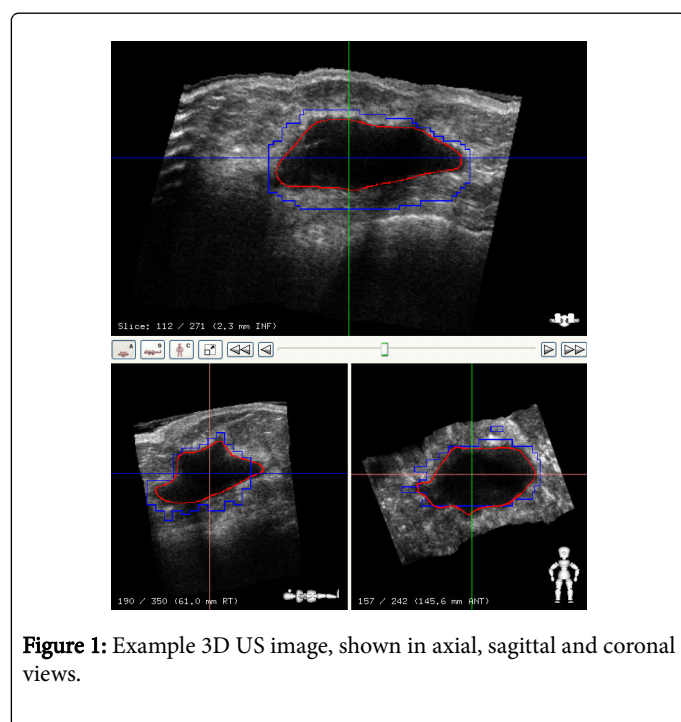


Figure 1: Example 3D US image, shown in axial, sagittal and coronal views.

CT and 3DUS Image acquisition

In clinical practice, measuring cavity shifts with 3DUS prior to each fraction has potential benefit for a) an a-PBI course, b) a photon or electron boost course, or c) during whole breast fractions. For an a-PBI course, the timescale between simulation and the last treatment fraction would typically be 2-3 weeks to include the time between simulation and planning.

For a boost course, the timescale would typically be 6-7 weeks, unless a second simulation for the boost is performed and used as an IGRT reference (which is our clinical practice). It is unclear whether there is any benefit to localizing the cavity for a whole breast course [9] which is an area of ongoing study, but if so the timescale would be 6-7 weeks.

In this study, we compared CT-to-CT shifts to 3DUS-to-3DUS shifts between two time points for each patient: 1) the initial simulation and 2) the boost simulation. This was to avoid additional dose to the patient other than what is being administered for their clinical treatment. The limitation of this timing is that it is not representative of the timescale of a-PBI, or a boost fraction if the second simulation is used as an IGRT reference. There is the potential for significant cavity shrinking in this timescale, which can affect the interpretation and calculation of shifts. Thus the comparison of shifts can be seen as a "worst-case" scenario for these clinical scenarios. Weed et al. [6] used a similar timescale in their work on using clips for breast IGRT.

All patients underwent an initial planning CT. Fiducials (BB's) were placed at the external lasers for identification of the simulation isocenter. 3DUS images of the lumpectomy cavity were acquired immediately after the planning CT scan and registered with the CT images. Prior to the electron boost treatment, a second CT/3DUS pair was acquired. BB's were placed on the treatment tattoos for the CT acquisition. The first and second pairs of registered images are referred to as CT1/3DUS1 and CT2/3DUS2, respectively.

In order to mitigate probe pressure, which could possibly cause displacement of the lumpectomy cavity, a generous amount of high-viscosity ultrasound gel was used. This allowed the therapists to sweep the probe smoothly over the breast with minimal pressure.

Data analysis

A radiation oncologist evaluated lumpectomy cavity visibility on each CT and US independently. The cavities were contoured independently on each CT and 3DUS dataset without reference to the other modality, using the tools provided in the Clarity Workstation software. CT images were contoured on the treatment planning system (Pinnacle3, Phillips Medical Systems) while 3DUS images were contoured on the Clarity Workstation using semi-automatic contouring tools.

The volume changes between CT1/CT2 and 3DUS1/3DUS2 were calculated. To validate the spatial position of cavities found on CT and 3DUS pairs, the volume overlap was computed using an off-line in-house tool. Figure 2 shows a representative CT and 3DUS registration in axial, sagittal, and coronal views.

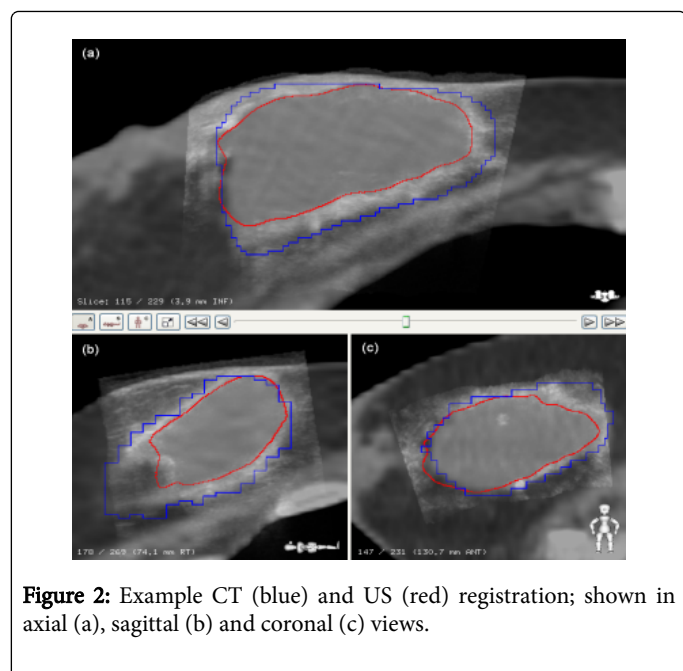


Figure 2: Example CT (blue) and US (red) registration; shown in axial (a), sagittal (b) and coronal (c) views.

One initial concern with using 3DUS for breast was that the ultrasound probe would displace breast tissue, and hence the cavity itself. This “probe pressure” effect is implicitly included in the comparison of shifts between modalities. To study this potential effect in more detail, we calculated the average displacement between the skin surface and the ultrasound probe. This was done by comparing each ultrasound frame to the external contour from the CT image. An algorithm was written for this purpose, which computes the average distance between the probe surface pixels of the ultrasound frames to the external contour. This parameter gives an estimation of probe pressure at the skin surface, although it is also affected by patient motion, patient breathing, and registration errors if any.

In order to validate the accuracy of 3DUS for IGRT positioning of the cavity, the shift in cavity position was calculated from CT, 3DUS and clips (when present) for each pair of images. For CT, the shift was calculated from the difference in the 3D centroid position of the CT contours, for 3DUS by calculating the shift required to center the contour from 3DUS1 onto the image from 3DUS2. For clips, the clip positions were identified manually on both CT1 and CT2 the difference between these centers of mass was used as the shift. This is likely how clips would be used in practice, although an automatic clip detection mechanism would likely be used instead of a manual technique.

For patients with clips, the average distance of the clips from the clip centroid position was calculated for both CT1 and CT2 scans. Comparison of any change in average clip position was compared to the change in average cavity radius or displacement between CT1 and CT2, as well as that between 3DUS1 and 3DUS2.

For each fraction, the margin needed to be added to the cavity volume on CT1 to encompass the cavity volume on CT2 was calculated. This was accomplished by creating a new CT1 structure with margin in the Clarity Workstation, and expanding the margin through visual inspection until the CT2 volume was included. This was repeated with both 3DUS and clip guided shifts applied.

The Wilcoxon Matched-Pairs Signed-Ranks Test was used to look for significant differences between groups. Correlations between groups were analyzed using the Pearson Correlation test, reporting the correlation coefficient r .

Although the data was analyzed once by a single user, it was validated by 4 users. The secondary effects of interobserver variations in target localization are not directly evaluated in this work, but are indirectly included in the shift comparison results, since the resulting uncertainties contribute the average and standard deviation of the differences between modalities.

Results

Of the 23 patients recruited in the study, two were not analyzed due to technical difficulties, and one removed herself from the trial, for a total of 20 patients. Of the 20 patients, 18(90%) had visible cavities on both CT and 3DUS.

The mean time between surgery and CT1 (for patients with visible cavities) was 54 days, with a standard deviation (SD) of 44 days. The 2 patients without visible cavities had times between surgery and CT1 of 112 and 98 days, respectively. The mean and SD between CT1 and CT2 were: 42, and 8 days.

The cavity volumes on CT1, CT2, 3DUS1 and 3DUS2 are shown for each patient in Figure 3. Mean and SD of these volumes are 64.0 ± 63.7 cc on CT1; 21.2 ± 22.9 cc on CT2; 47.7 ± 42.7 cc on US1; and 13.8 ± 16.9 cc on US2. 3DUS volumes were on average $32 \pm 24.2\%$ smaller than CT volumes. In 14 patients the volumes between the two time points shrank $62 \pm 28\%$ on CT and $71 \pm 23\%$ on the 3DUS. A good correlation was seen between percent change in the volumes on 3DUS and CT scan (Figure 3). In general a decrease is seen in the lumpectomy cavity volumes as a function of time from surgery (Figure 4).

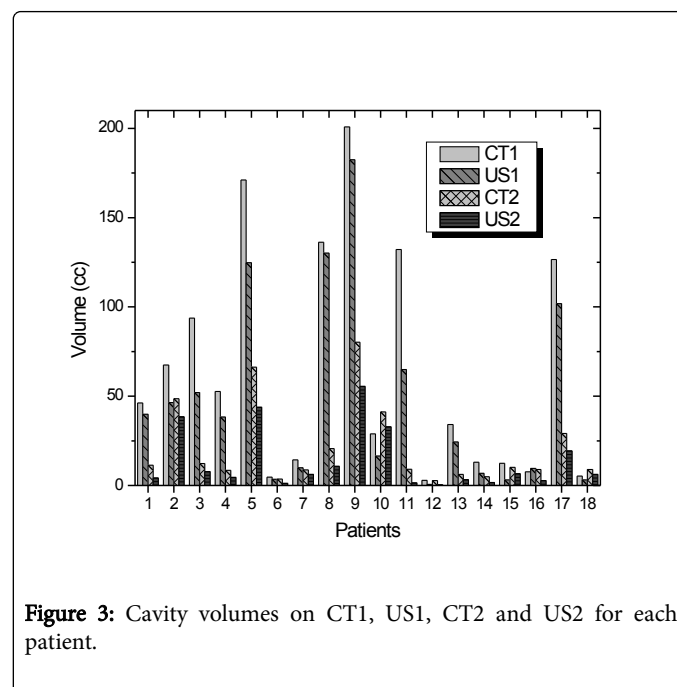


Figure 3: Cavity volumes on CT1, US1, CT2 and US2 for each patient.

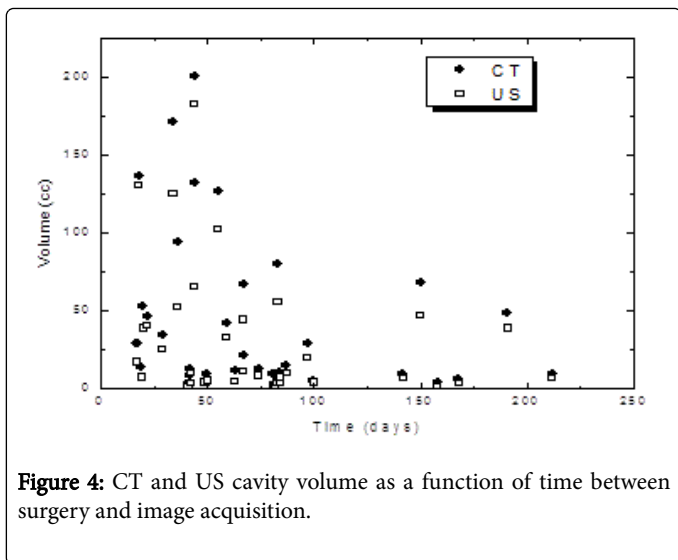


Figure 4: CT and US cavity volume as a function of time between surgery and image acquisition.

The decrease in the average distance from the clips to their centroid between CT1 and CT2 is displayed in Figure 5. Also shown for comparison is the average radial decrease of the lumpectomy cavity as seen on the CT and US. The average radius of the clip centroid decreases over the course of treatment, and it follows the same trend as the cavity shrinking on CT and US. There is a significant correlation between the average radial decrease in clip distances and the decrease in both the CT ($r=0.9$; $p < 0.02$) and 3DUS ($r=0.9$; $p < 0.004$) effective cavity radii.

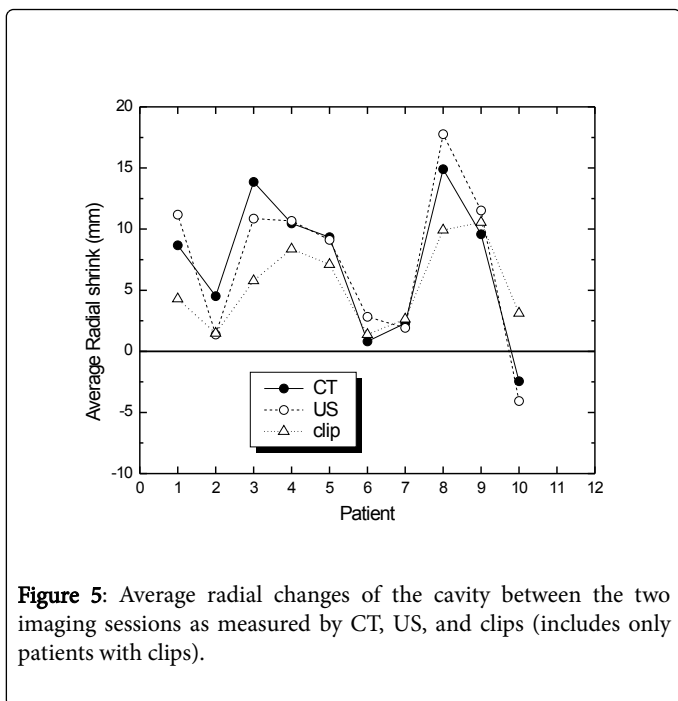


Figure 5: Average radial changes of the cavity between the two imaging sessions as measured by CT, US, and clips (includes only patients with clips).

The average and SD of the differences in the skin surface between CT and 3DUS was 4.7 ± 2.4 mm. This effect includes a) probe pressure, b) patient motion between scans, c) patient breathing, d) registration errors and e) interobserver. Overall any probe pressure effects at the skin surface are expected to diminish at depth.

The volume overlap between cavities contoured independently on CT and 3DUS is $76.0 \pm 21.2\%$. An overlap of less than 70% was seen in only 25% of the volumes. CT and 3DUS accentuate different features of the cavity, and thus complete overlap is not necessarily expected; however this can still be viewed as a rough indicator of registration accuracy. The volume overlap is plotted as a function of time from surgery to imaging in Figure 6.

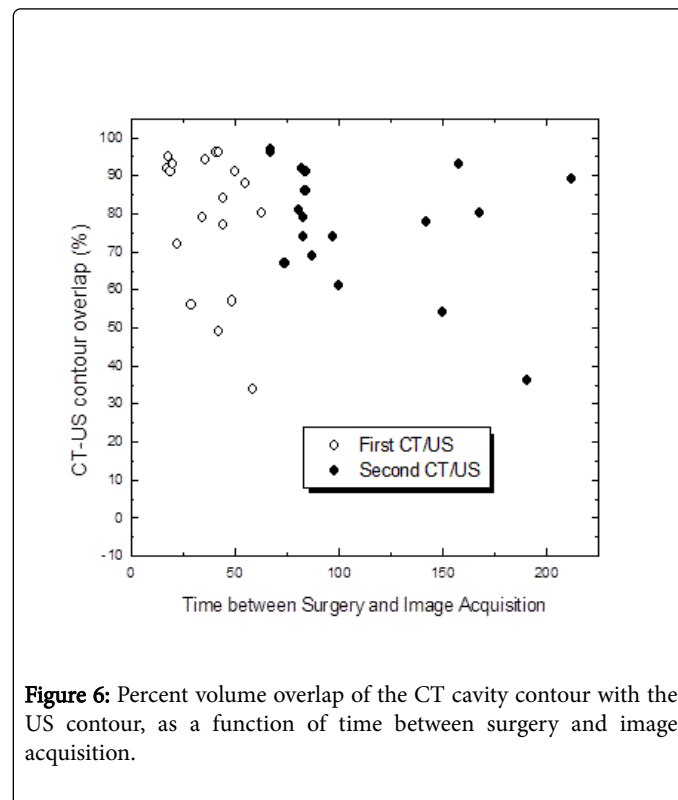
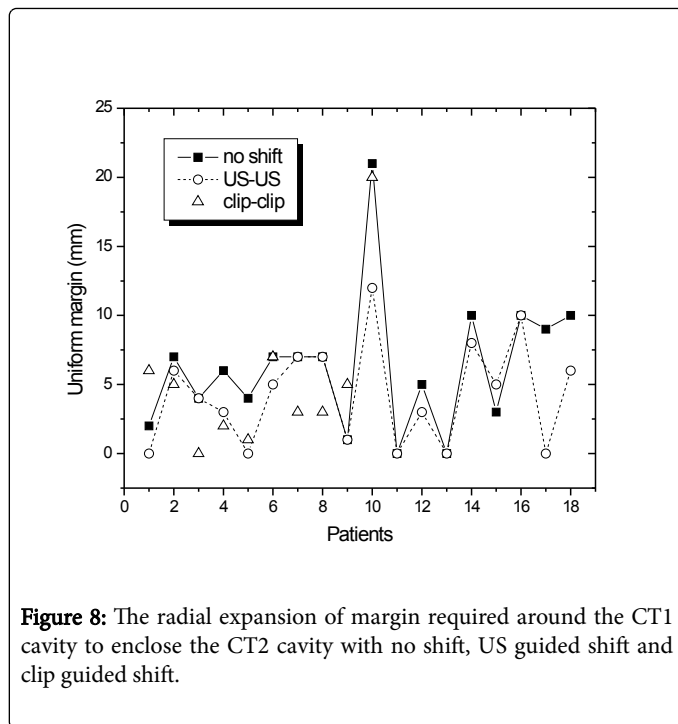
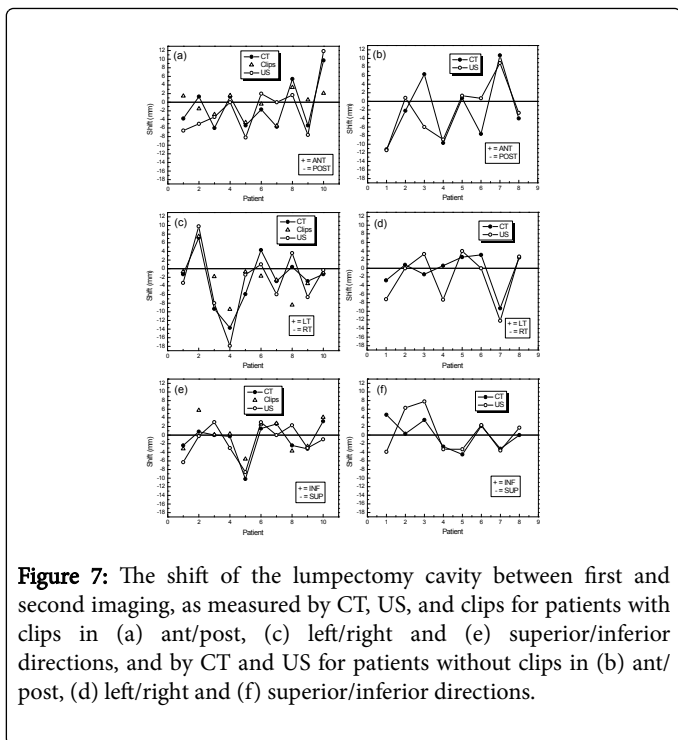


Figure 6: Percent volume overlap of the CT cavity contour with the US contour, as a function of time between surgery and image acquisition.

There is no correlation (Pearson correlation $p > 0.1$) between the percent overlap and time from surgery indicating that the cavities as seen on 3DUS or CT scan tend to change in tandem in the same direction. The cavity displacements calculated on CT, 3DUS, and clips are shown in Figure 7.

The mean, median and SD for all directions are summarized in Table 1. The differences between modalities, as well as the p-values, are summarized for all patients (CT and 3DUS only), as well as for the subset of patients with clips (all modalities) in Table 2. The displacements predicted by CT, US and clips were not significantly different ($p > 0.05$).

The margins needed to be added to the cavity volume on CT1 to encompass the cavity volume on CT2 when no shifts, 3DUS guided or clip guided shifts are made are shown in Figure 8. The mean and SD are significantly smaller 4.3 ± 3.7 mm when 3DUS based shifts were made compared with no shifts 6.3 ± 4.9 ($p < 0.007$). When only the subset of patients with clips is analyzed, the margins required are 6.6 ± 5.5 mm with no shifts, 4.5 ± 3.8 mm with 3DUS shifts, and 5.2 ± 5.7 mm with clip shifts. Although the difference in margins between no shifts and both US and clips are significant ($p < 0.004$ and $p < 0.03$, respectively), the difference between US and clip based shifts are not significant ($p > 0.7$).



Shift method	Mean [mm]				Median [mm]			
	(Standard Deviation)				(Range)			
	A/P	L/R	S/I	Radial	A/P	L/R	S/I	Radial
CT shifts (all patients)	-1.5 (6.3)	-1.6 (5.3)	-0.6 (3.6)	8.3 (6.3)	-3 (-11.2:10.7)	-1.3 (-13.7:7.1)	0 (-10.2:4.7)	7.3 (2.4:14.5)
US shifts (all patients)	-1.8 (6.1)	-2.5 (6.7)	-0.6 (4.3)	9.7 (4.1)	-1.3 (-11.4:11.9)	-0.9 (-17.9:9.8)	-0.6 (-8.6:7.8)	10.1 (2.5:16.7)
Clip shifts (clip patients)	-0.6 (3)	-2.2 (4.6)	0.1 (3.7)	3.4 (3.7)	0.1 (-5.5:3.5)	-1.8 (-9.4:7.5)	0.2 (-5.6:5.8)	3.2 (0.0:9.8)

Table 1: Mean, standard deviation, median and range of the lumpectomy cavity displacements according to CT, 3DUS and clips, in the anterior/posterior (A/P), left/right (L/R), superior/inferior (S/I) and radial directions. (Results for clips are reported only for the subset of patients with clips).

	Mean [mm]			Median [mm]			Wilcoxon		
	(Standard Deviation)			(Range)			p-value		
	A/P	L/R	S/I	A/P	L/R	S/I	A/P	L/R	S/I
CT and US (all patients)	-0.3 (4.6)	-0.9 (3.5)	0 (3.6)	0.2 (-12.3:8.3)	-1.4 (-7.9:4.7)	0.2 (-8.6:6.0)	0.9	0.4	0.8
CT and US (clip patients)	-0.5 (3.8)	-0.4 (3.2)	-0.4 (3)	-1.8 (-6.3:5.7)	-0.5 (-4.2:4.5)	-0.4 (-4.2:4.7)	0.6	0.7	0.8
CT and clips (clip patients)	0.4 (4)	0.3 (4.9)	1.1 (2.1)	0.5 (-7.6:6.0)	0.4 (-8.8:7.5)	0.6 (-1.3:5.0)	0.6	0.6	0.2

US and clips (clip patients)	0.9 (5.6)	0.7 (5.7)	1.4 (3.7)	1.7 (-9.8:8.2)	1.6 (-12.0:8.5)	2.9 (-5.9:6.0)	0.6	0.4	0.2
---------------------------------	--------------	--------------	--------------	-------------------	--------------------	-------------------	-----	-----	-----

Table 2: Mean, standard deviation, median and p-value of the differences in cavity displacements between first and second simulation sessions, as measured by CT, US and clips.

The mean and SD of the cavity volumes from CT2 which lied outside the cavity from CT1 is 3.2 ± 5.9 cc without any shifts, 2.4 ± 4.7 cc when shifts were done according to the US and 2.8 ± 7.3 cc when the shifts were made according to the clips. The average volume of the treatment lumpectomy cavity outside the planning cavity was significantly less after adjustment according to either the clips or US-IGRT ($p < 0.05$ and $p < 0.03$ respectively), while no significant difference was seen between the two shifting methods ($p > 0.9$).

Discussion and Conclusions

Technological advances over the years have allowed the successive improvement in the design of the radiation therapy plans. Better volume definitions and image guided localization while on treatment may permit adding smaller margins to the target volumes and thus resulting in less normal tissue receiving unintended radiation. Smaller volumes of tissue in the path of the beam allow the delivery of higher doses per fraction in fewer treatments. Recently a general trend in radiation treatments has been emerging to accelerate fractionation and target smaller volumes thus decrease the burden of multiple treatments on the patients. With the smaller fields accurate targeting is of increased importance. The breast LC is an excellent target for US guided imaging without using ionizing radiation.

The fraction of patients with visible cavities on both CT and US (90%) was high, considering the wide range of time intervals 17 to 168 days between surgery and the first planning CT. Consistent with other reports we found that the average volume of the cavities as contoured on 3DUS was smaller than those contoured on CT [8-10]. Because of the difference in the physical principles of imaging, 3DUS and CT exhibit different tissue characteristics. The US better defines the seroma/fluid cavity with its wall while the fibrosis and tissue remodeling are better seen on the CT scan. However the cavity on the CT scan images can be confounded by dense normal parenchyma, or retroareolar tissue. For purposes of treatment planning, the fusion of CT and 3DUS can be used for delineating the CTV, by combining the information from each modality. For IGRT, the cavity as seen on 3DUS, which at times may be smaller than the CTV, can be a good target to quantify interfractional cavity motion if the shifts calculated from 3DUS agree with the shifts calculated from CT, which is addressed in this study.

Cavity shrinking of more than 60% was seen between the two sets of both CT and 3DUS volumes in the majority (78%) of the patients. This is in general agreement with cavity shrinking as determined by CT reported by others [11-16]. There was an increase in the cavity seen on both CT and 3DUS in two cases, and either CT or 3DUS in two cases. A discrepancy between CT and US was mostly seen when the cavity volumes were small, which is expected since a small error in contouring lead to a large percent change in volume.

Shrinking of the clip-bounded volume has been previously reported [17,18]. We have also observed a similar trend in this study. When we compared the decrease in effective radius from the clips' position to that of the cavity as contoured on both CT and 3DUS, we have found

that there is a direct correlation between all three measures of cavity change. The clip volume change, in all cases except one, was smaller or close to the cavity volumes on 3D US and CT which is consistent with the hypothesis that tissue immediately surrounding the cavity is contracting [19].

The Clarity system registers all CT and 3DUS images acquired in this study directly using the correspondence between the respective imaging coordinate systems. The main purpose of the study is to compare shifts, which already includes any potential registration uncertainties, but studying the quality of the registration in isolation can be estimated by different methods. One method to evaluate the quality of the registration is to validate the correspondence of the skin surface on both modalities. Our methodology to make this comparison compares the surface of the original 2D ultrasound slices to the CT external contour. Although this method is only approximate, it provides an estimation of registration accuracy. The differences between the ultrasound probe trajectory and the skin surface include the effect of probe pressure (which was kept to a minimum), patient motion between scans, patient breathing, and registration errors. The median discrepancy was 4.5 mm, which can partially be attributed to breathing motion which has been observed to be 3 mm on average with a maximum of up to 10 mm [20-22]. This indicates that probe pressure at the skin surface is not clinically significant when an adequate amount of high viscosity gel is used and the ultrasound scanner is trained to apply minimal pressure.

The small discrepancy in registration observed at the skin surface is assumed to decrease with depth within the patient. We also validated the registration by comparing the overlap of CT and 3DUS cavity contours. We found a good overlap 79% for CT1/US1 and 78% for CT2/US2. Considering the known differences in cavity definition between both modalities, this is consistent with the 72% overlap found by Berrang et al. [8]. We also visually compared the grayscale images, including corresponding structures visible in both images such as the chest wall, and found good visual registration between all images. Interestingly, the percent overlap was not impacted by the time interval between the surgery and the time of imaging, indicating that the US and CT volumes change concordantly.

The subject of interfractional cavity displacement has not been extensively studied in the literature. Weed et al. [6] reported the motion of both the CT cavity and clips as a surrogate for the cavity to quantify this effect. Our displacements of the CT cavity are on the same order as that measured in their study, although our mean displacements are slightly smaller and the standard deviations slightly larger. It is unclear whether they computed statistics on the absolute value of directional displacements or the signed displacements as we did, and they did not report statistics on the radial displacements, making a direct comparison difficult. However, we found, as they did, that although average cavity displacements are small, they can vary up to 1-1.8 cm indicating that image guidance may be beneficial. It should again be stressed that the timescale between simulation and treatment scans in this study, as in the Weed et al. [6] study, are much larger than

that which would occur for EBPBI patients, since the study was carried out on patients receiving whole breast treatments. Thus, cavity changes over time and their effect on cavity displacements would likely be less in the EBPBI patient population.

Fatuanase et al. [23] reported radial shifts of 6 ± 2 mm using cone beam CT, with 33% having shifts larger than 10 mm. Although this variation is smaller than that found in our study, their results do not include patient setup errors, since they first corrected for bony anatomy misalignment. Kim et al. [24] found an average shift of 7 mm, and found that breathing motion was within 3 mm. Hasan et al. [25,26] found displacements of the bony anatomy of 7 ± 2 mm, with a further clip displacement of 4 ± 3 mm. They also found an error in clip registration of 3 ± 2 mm relative to the cavity. Our study compares the displacements measured by 3DUS, clips and well as CT. We found no statistically significant difference between cavity displacements measured by each modality. This indicates that 3DUS is an acceptable modality for breast IGRT.

The minimum margins required to cover the cavity when shifting the patient with 3DUS was smaller compared to not shifting the cavity. A decrease was observed with clips as well, similarly to that reported by Weed et al. [6]. Due to the smaller number of patients with clips present in this study, the smaller margins required with 3DUS versus clips is not statistically significant. We also compared the volume of the cavity which fell outside the planned cavity volume, with and without shifts. We found a statistically significant decrease in this volume when clips or 3DUS were used to shift the cavity. Although the volume found outside the planned cavity volume was smaller for 3DUS than clips, this study did not have sufficient patients with clips to establish a statistically significant difference.

Wong et al. [4] and Landry et al. [27] also studies Clarity for breast but did not compare to clips. The study did evaluate the usefulness of 3DUS by tracking and identifying the tumor bed (TB) for planning and daily localization before treatment.

Based on these results, both clips and 3DUS are adequate and can be used to compensate for cavity motion for breast radiotherapy. In our institution, we have clinically implemented 3DUS for breast IGRT since our surgeons do not routinely place clips, and 3DUS does not give additional imaging dose to the patient.

References

1. Baglan KL, Sharpe MB, Jaffray D, Frazier RC, Fayad J, et al. (2003) Accelerated partial breast irradiation using 3d conformal radiation therapy (3d-crt). *Int J Radiat Oncol Biol Phys* 55: 302-311.
2. Landis DM, Luo W, Song J, Bellon JR, Punglia RS, et al. (2007) Variability among breast radiation oncologists in delineation of the postsurgical lumpectomy cavity. *Int J Radiat Oncol Biol Phys* 67: 1299-1308.
3. Petersen RP, Truong PT, Kader HA, Berthelet E, Lee JC, et al. (2007) Target volume delineation for partial breast radiotherapy planning: Clinical characteristics associated with low interobserver concordance. *Int J Radiat Oncol Biol Phys* 69: 41-48.
4. Wong EK, Truong PT, Kader HA, Nichol AM, Salter L, et al. (2006) Consistency in seroma contouring for partial breast radiotherapy: Impact of guidelines. *Int J Radiat Oncol Biol Phys* 66: 372-376.
5. Vicini F, Winter K, Straube W, Wong J, Pass H, et al. (2005) A phase i/ii trial to evaluate three-dimensional conformal radiation therapy confined to the region of the lumpectomy cavity for stage i/ii breast carcinoma: Initial report of feasibility and reproducibility of radiation therapy oncology group (rtog) study 0319. *Int J Radiat Oncol Biol Phys* 63: 1531-1537.
6. Weed DW, Yan D, Martinez AA, Vicini FA, Wilkinson T, et al. The validity of surgical clips as a radiographic surrogate for the lumpectomy cavity in image-guided accelerated partial breast irradiation. *Int J Radiat Oncol Biol Phys* 60: 484-492.
7. Kass R, Kumar G, Klimberg VS, Kass L, Henry-Tillman R, et al. (2002) Clip migration in stereotactic biopsy. *American J. Surgery* 184: 325-331.
8. Berrang TS, Truong PT, Popescu C, Drever L, Kader HA, et al. (2009) 3d ultrasound can contribute to planning ct to define the target for partial breast radiotherapy. *Int J Radiat Oncol Biol Phys* 73: 375-383.
9. Fontanerosa D, van der Meer S, Bamber J, Harris E, O'Shea T, et al. (2015) Review of ultrasound image guidance in external beam radiotherapy: I. Treatment planning and inter-fraction motion management *Phys Med Biol* 60: 77-114.
10. Rabinovitch R, Finlayson C, Pan Z, Lewin J, Humphries S, et al. (2000) Radiographic evaluation of surgical clips is better than ultrasound for defining the lumpectomy cavity in breast boost treatment planning: A prospective clinical study. *Int J Radiat Oncol Biol Phys* 47: 313-317.
11. Hurkmans C, Admiraal M, van der Sangen M, Dijkmans I (2009) Significance of breast boost volume changes during radiotherapy in relation to current clinical interobserver variations. *Radiother. Oncol* 90: 60-65.
12. Jacobson G, Betts V, Smith B (2006) Change in volume of lumpectomy cavity during external-beam irradiation of the intact breast *Int J Radiat Oncol Biol Phys* 65: 1161-1164.
13. Oh KS, Kong F-M, Griffith KA, Yanke B, Pierce LJ (2006) Planning the breast tumor bed boost: Changes in the excision cavity volume and surgical scar location after breast-conserving surgery and whole-breast irradiation. *Int J Radiat Oncol Biol Phys* 66: 680-686.
14. Prendergast B, Indelicato DJ, Grobmyer SR, Saito AI, Lightsey JL, et al. The dynamic tumor bed: Volumetric changes in the lumpectomy cavity during breast-conserving therapy. *Int J Radiat Oncol Biol Phys* 74: 695-701.
15. Sharma R, Spierer M, Mutyala S, Thawani N, Cohen HW (2009) Change in seroma volume during whole-breast radiation therapy. *Int J Radiat Oncol Biol Phys* 75: 89-93.
16. Tersteeg RJ, Roesink JM, Albrechts M, Wárlám-Rodenhuis CC, van Asselen B (2009) Changes in excision cavity volume: Prediction of the reduction in absolute volume during breast irradiation. *Int J Radiat Oncol Biol Phys* 74: 1181-1185.
17. Goldberg H, Prosnitz RG, Olson JA, Marks LB (2005) Definition of postlumpectomy tumor bed for radiotherapy boost field planning: CT versus surgical clips. *Int J Radiat Oncol Biol Phys* 63: 209-213.
18. Kim L, Vicini F, Yan D, Vargas C, Martinez A, et al. (2004) Reduction of PTV margin for accelerated partial breast irradiation using on-line detection of surgical clips. *Int J Radiat Oncol Biol Phys* 60: 336.
19. Kim LH, Vicini F, Yan D (2008) What do recent studies on lumpectomy cavity volume change imply for breast clinical target volumes? *Int J Radiat Oncol Biol Phys* 72: 1-3.
20. Böhmer D, Feyer P, Harder C, Körner M, Sternemann M, et al. (1998) Verification of set-up deviations in patients with breast cancer using portal imaging in clinical practice. *Strahlenth. und Onkol* 174: 36-39.
21. Smith RP, Bloch P, Harris EE, McDonough J, Sarkar A, et al. (2005) Analysis of interfraction and intrafraction variation during tangential breast irradiation with an electronic portal imaging device. *Int J Radiat Oncol Biol Phys* 62: 373-378.
22. Van Tienhoven G, Lanson J, Crabeels D, Heukelom S, Mijnheer B (1991) Accuracy in tangential breast treatment set-up: A portal imaging study. *Radiother. Oncol* 22: 317-322.
23. Fatunase T, Wang Z, Yoo S, Hubbs JL, Prosnitz RG, et al. (2008) Assessment of the residual error in soft tissue setup in patients undergoing partial breast irradiation: Results of a prospective study using cone-beam computed tomography. *Int J Radiat. Oncol Biol Phys* 70: 1025-1034.
24. Kim L, Vicini F, Yan D (2005) Clinically achievable accuracy of online localization of the lumpectomy cavity using surgical clips. *Int. J Radiat Oncol Biol Phys* 63: 211.

-
25. Hasan Y, Kim L, Weed DW, Kestin L, Martinez A (2005) Image guidance in external beam accelerated partial breast irradiation: Comparison of surrogates for the lumpectomy cavity. *Int J Radiat Oncol Biol Phys* 63: 138.
26. Hasan Y, Kim L, Martinez A, Vicini F, Yan D (2008) Image guidance in external beam accelerated partial breast irradiation: Comparison of surrogates for the lumpectomy cavity. *Int J Radiat Oncol Biol Phys* 70: 619-625.
27. Landry A, Berrang T, Gagne I, Popescu C, Mitchell T, et al. (2014) Investigation of variability in image acquisition and contouring during 3D ultrasound guidance for partial breast irradiation, *Radiat Oncol* 9.