

Alignment of Buccally Erupted Canine Using HANT Wire

Parijat Chakraborty^{1*}, Kamlesh Singh², Ragni Tandon², Richa Dhingra² and Pranshu Mathur²

¹Department of Orthodontics, Private Practitioner, Consultant Orthodontist, Lucknow, India

²Department of Orthodontics and Dentofacial Orthopedics, Saraswati Dental College, Lucknow, India

Abstract

Ectopic teeth develop when displaced from their normal position. Any permanent tooth can be ectopic, and the cause may be both genetic and environmental. Orthodontic treatment is justifiable for aesthetic reasons. Subsequently a careful diagnosis along with a proper treatment plan for ectopically erupting permanent maxillary canines requires timely management by the orthodontist. The purpose of this case report is to illustrate an approach involving management using HANT wire.

Keywords: HANT wire • Orthodontic • Ectopic teeth

Introduction

The failure of permanent teeth to erupt into their normal position in the dental arches is usually due to a discrepancy between tooth size and overall arch length [1]. The prevalence of permanent maxillary canine impaction or ectopic eruption in the general population is approximately 1-2% in which palatally displaced canine is twice as much of the buccally placed canine. But, ironically buccally placed canines are seen more in clinical practice [2] (Figure 1). Orthodontic tooth movement of buccally placed canines is usually difficult as it is always related with problems of severe crowding, midline deviation, involvement of long root movement along with its angulations, risk of damage to adjacent tooth structures and risk of gingival recession [3]. For the management of ectopic canines, the approaches have been classified accordingly: use of sliding mechanisms and other using loop mechanics. Possible means for creating for space the canine is interproximal reduction, arch expansion, distal movement of molars, extraction, or any type of combination of the above. Alignment of malpositioned teeth is generally treated using multi-looped Stainless Steel (SS) wires, coaxial wires, Nickel titanium (NiTi) wires, or Heat Activated Nickel Titanium (HANT) wires. However, when ectopically erupted canines are aligned with NiTi wires, due to their bulky root structure, there is a risk of round tripping of adjacent teeth. This creates a load on the anchorage leading to anchor loss and prolongs the treatment duration [4,5]. The upper canines' significance to dental esthetics and functional occlusion makes the decision a very serious one. The purpose of this report is to illustrate an approach involving orthodontic management using HANT wire. The case was treated through an orthodontic nonextraction fixed appliance mechanotherapy for successful alignment of buccally ectopic upper right canine.

Case Report

The patient was a North Indian female who presented at the age of 12 years and 4 months to the Department of Orthodontics with a chief complaint of malposed canine. On examination, the individual had Class I malocclusion on a Class II skeletal base. The upper incisors were normal, with a 2 mm space in between the maxillary central incisors. The overjet was normal (3 mm), and the overbite was 50% (4 mm). There was retained deciduous canine present in the 1st quadrant. The permanent right maxillary canine was highly

placed buccally between the 1st and 2nd maxillary premolars (Figure 2). The Orth Pantograph (OPG) showed that all permanent teeth roots appeared to be of normal size, morphology, and at a normal developmental stage along with a retained deciduous canine in the first quadrant. The right permanent maxillary canine was positioned in between 1st and 2nd premolar along with its root highly positioned. The root of right 1st premolar was a bit short and mesially tilted towards the lateral incisor root as appreciated in the radiograph (Figure 3). The cephalometric analysis showed ANB value of 6°C, which suggests that the patient had a Class II skeletal pattern. This was supported by the Wits analysis (+3 mm). The ratio of lower to total anterior face height was average (67%).

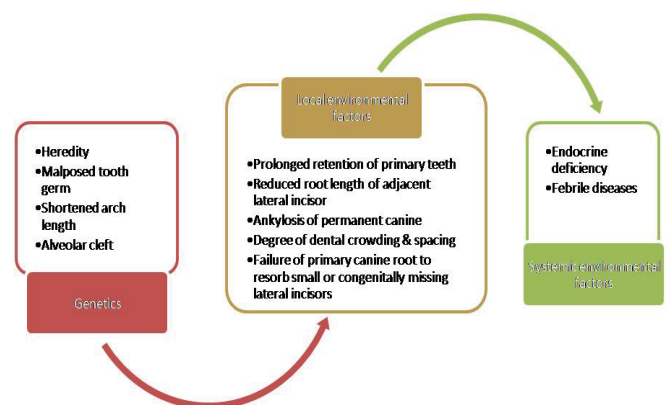


Figure 1. Etiology of ectopic/malposed canine.

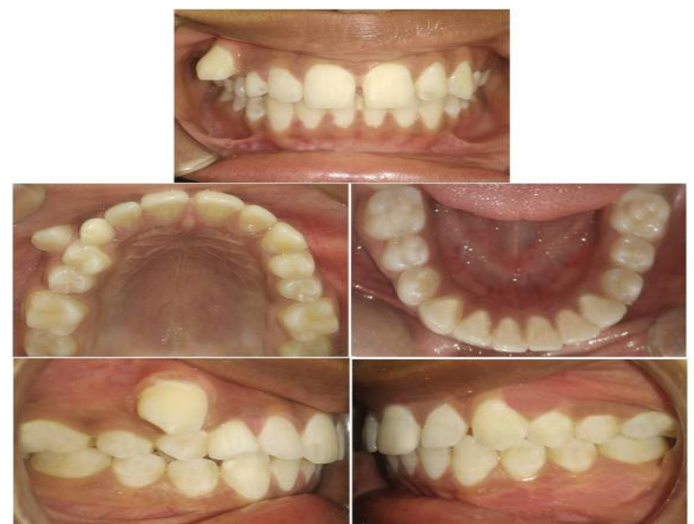

Figure 2. Pre-treatment intraoral photographs.

*Address for Correspondence: Chakraborty P, Department of Orthodontics, Private Practitioner, Consultant Orthodontist, Lucknow, India, E-mail: parijatchak@gmail.com

Copyright: © 2021 Chakraborty P, et al. This is an open-access article distributed under the terms of the Creative Commons Attribution License, which permits unrestricted use, distribution, and reproduction in any medium, provided the original author and source are credited.

The Maxillary-Mandibular Plane Angle (MMPA) was lower than normal range indicating the horizontal growth pattern (22°). The upper and lower incisors were proclined at 118° and 105° respectively. The lower lip lay 3mm ahead of the Ricketts E-plane. The patient was in cervical vertebral completion stage (Figure 3). Model analysis showed a mild space in upper arch (2 mm), 6 mm mesiodistal width of deciduous canine and 9 mm that of permanent canine. In occlusion, the patient had a 3 mm overjet, average, and an overbite of 4 mm, and coincident lower dental midline to facial midline. The problem list is as follows: Class II skeletal pattern, Proclined maxillary and mandibular incisors, overbite of 4 mm and overjet of 3 mm, rotated. Full unit Class I molar relationship on both sides, the right maxillary canine highly positioned with a retained deciduous canine on its actual place.

Results and Discussion

Treatment aims and objective

To achieve ideal overjet and overbite, Level and align the dentition in the upper arch, Maintain Class I molar relationship on both sides, create space for upper right canine by extraction of deciduous teeth, bring the right maxillary canine into the arch.

Treatment plan and rationale

The treatment was planned to be carried only in the upper arch by leveling and aligning and creating space for the highly placed canine and simultaneously bringing the canine into the arch. This was achieved by extraction of the deciduous canine and proper leveling and aligning of the arch. Upper 0.022" × 0.028" preadjusted Edgewise appliances with an MBT prescription was used to consolidate the space. Rotated 2nd premolars on each quadrant was corrected using elastic chains from premolars to molars using bonded lingual buttons on premolars and soldered buttons on molar bands. HANT wire was used to bring the canine to its actual position. Retention was to be achieved using a lingual bonded retainer as well as Beggs retainer.

Treatment progress and result

The upper arch was bonded using 0.022" × 0.028" slot preadjusted

edgewise appliance with an MBT prescription with bands on both the 1st molars. First preformed arch wire to be ligated in the arch was 0.016 tapered upper NiTi for leveling and aligning and correction of minor rotations of 2nd premolars on both sides and elastomeric chain was used to consolidate the space available between the maxillary centrals (Figure 4). The space created for the maxillary canine was maintained meanwhile by a sleeve. After one month the arch was properly aligned and there was adequate space available for accommodating the canine. On the 3rd appointment, a 0.016" HANT upper tapered preformed arch wire was ligated including the canine (Figure 4). An interval of two weeks was advised to the patient for keen observation of the movement. The wire was re-ligated in every alternate appointment. Changes were appreciable from the first month after the wire was ligated first. The canine rotated along its long axis and mesialised just above the desired position in a span of three months.

The main arch wire was then changed to 0.016" × 0.022" NiTi but this time the canine was not ligated instead a piggy back using a 0.012" NiTi auxiliary wire was placed in the main slot of the canine bracket and upper slot of the rest of the brackets. A Figure of 8 tie was given on the anterior dentition mesial to the right maxillary canine and also on the teeth posterior to the canine making it as a single unit. 4 months later, the canine was in the arch at its position and an intra oral periapical radiograph of that region appreciated the root of the canine to be distally tilted towards the short root of the 1st premolar. Hence, to correct the root tipping we repositioned the canine bracket and the 0.016" × 0.22" NiTi wire with 2nd order bends was ligated. Two appointments later, root tip was corrected, and the arch wire was changed to 0.017" × 0.025" SS rectangular wire. The wire was stabilized for around four months and then the settling wire 0.014" SS was placed for a month for proper settling of the occlusion. Debonding of the arch was done and a lingual bonded retainer was bonded palatally from maxillary right canine to left canine subsequently, also a wraparound retainer for the upper arch was delivered the next day with necessary instructions (Figure 5).

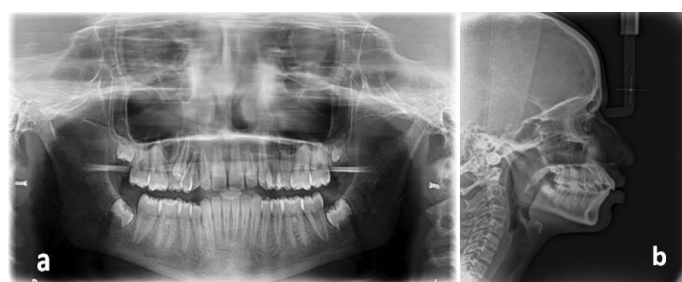


Figure 3. (a) Pre-treatment orthopantomograph (b) Pre-treatment lateral cephalography.

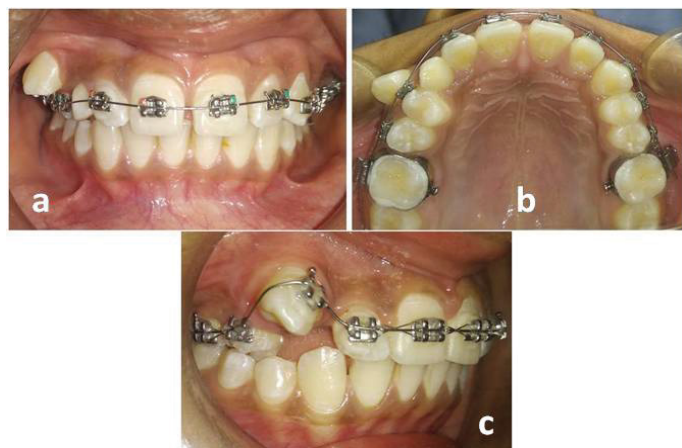


Figure 4 (a-c). 0.016" Ni-Ti wire ligated in the upper arch; 0.016" HANT wire ligated.

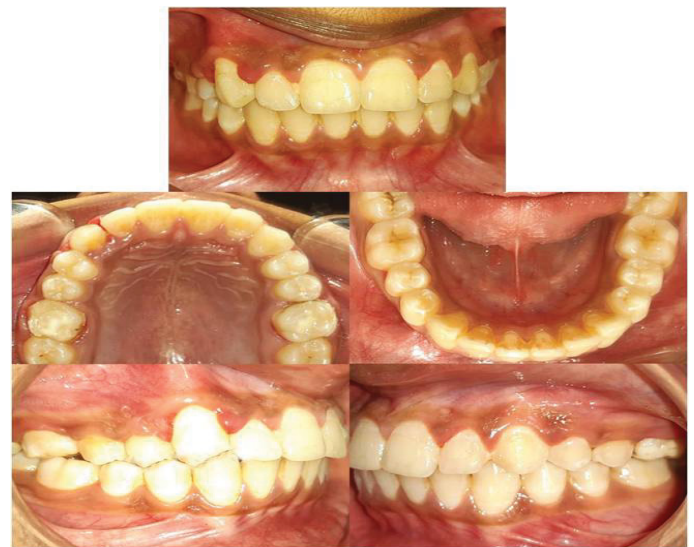

Figure 5. Post-treatment intraoral photographs.

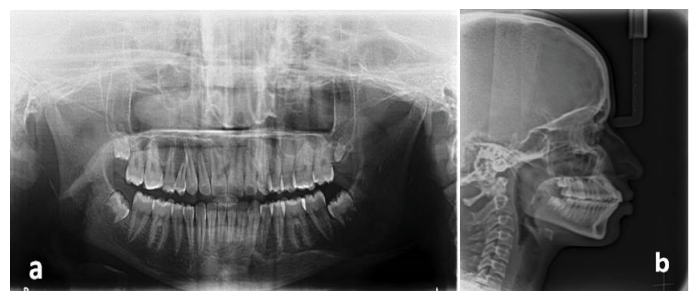


Figure 6. (a) Post-treatment orthopantomograph; (b) Post treatment lateral cephalography.

Post treatment radiographic findings

The finishing OPG showed that the roots are generally of acceptable parallelism except for the root of the upper right canine and upper 1st premolars, which appeared to be distally tipped and short respectively. Second-order bends were placed into a 0.017 × 0.025" SS arch wire to correct this during the finishing phase of the case. There has been no significant change in the root angulation of canine as well as the position of the developing lower-third molars, which remained unerupted (Figure 6). The post treatment cephalometric analysis showed that ANB value has reduced from 6° to 5°. Interestingly, the Wits reduced indicating an improvement in the skeletal pattern. The MMPA value did not change significantly during treatment indicating no extrusion or intrusion of posteriors. The upper incisors were proclined by 1° during the treatment; which is within the normal range. There was also no marked change in the relationship of the upper and lower lip to the E-plane.

Conclusion

This case report demonstrates the careful planning of creating space while maintaining both the molar relation and midline unchanged, and the orthodontic mechanics to deliver light, controlled force using HANT wire along

with keeping in mind the anchoring units. The use of HANT eliminated the use of loops which require precise fabrication and force application.

References

1. McBride, Jones. "Traction: A Surgical/Orthodontic Procedure." *Am J Orthod* 73 (1979): 287-299.
2. Alice Cameron and Serryth Colbert. "A Review of Diagnosis and Management of Impacted Maxillary Canines." *J Amnt Assoc* 140 (2009): 1485-1493.
3. Hessa M Alkhal, Bakr Rabie and Ricky WK. Wong. "Orthodontic Tooth Movement of Total Buccally Blocked-Out Canine: A Case Report." *Case J* 2 (2009): 7245.
4. Avesh Sachan and Pan Chaturvedi. "Orthodontic Management of Buccally Erupted Ectopic Canine with Two Case Reports." *Con temp Clin Dent* 3 (2012): 123-128.
5. MitaliBrijmohan Sharma and SuchitaTarvade Daokar. "Alignment of Buccally Placed Canine with Modified Trans Palatal Arch." *Int J Orthod Rehabil* 11 (2020): 33-37.

How to cite this article: Parijat Chakraborty, Kamlesh Singh, Ragni Tandon, and Richa Dhingra, et al. "Alignment of Buccally Erupted Canine Using Hant Wire." *Clin Case Rep* 11 (2021): 1424.