

An Autopsy Case of Asphyxia Caused by Uncontrolled Hemorrhage Following Transbronchial Lung Biopsy

Mayumi Watanabe, Kana Unuma*, Yohsuke Makino, Ayumi Komatsu, Atsushi Yamada, Hisashi Nagai, and Koichi Uemura

Department of Forensic Medicine, Graduate School of Medical and Dental Sciences, Medical and Dental University, Tokyo, Japan.

Abstract

Bronchoscopy is an important technique and flexible bronchoscopy procedures are considered comparatively safe. Notwithstanding, we here describe a woman who died of asphyxia caused uncontrolled hemorrhage following transbronchial lung biopsy. A medico-legal autopsy disclosed a small wound with clotted blood at the point of the transbronchial lung biopsy. The right lung was filled with a large volume of blood. Other organs showed no significant findings. Thus, this woman died from asphyxia associated with uncontrolled hemorrhage from the site of a transbronchial lung biopsy. We believe that our case is very instructive for safety bronchoscopy procedures.

Keywords: Bronchoscopy; Transbronchial lung biopsy; Haemorrhage; Hemostasis; Autopsy

Abbreviations: CT: Computed Tomography; GGO: Ground Glass Opacities; TBLB: Transbronchial Lung Biopsy

Introduction

Bronchoscopy is an important endoscopic technique of visualizing the inside of the airways for the diagnosis and therapy. In 1966, Ikeda invented the flexible bronchoscope [1], nowadays flexible bronchoscopy is commonly performed on conscious patients as a local anesthetic or under moderate sedation and used to diagnose and treat many lung and airway diseases worldwide. Flexible scopes can be inserted into the airways through the nose, mouth, or a tracheostomy. Because they usually have diameters of 5–6 mm, curved subsegmental bronchi can be observed. Samples can be obtained by transbronchial biopsy, bronchoalveolar lavage, brushing, transbronchial needle aspiration, and transbronchial lung biopsy (TBLB). Flexible bronchoscopy procedures are considered comparatively safe: one large survey [2] found that in 103,978 diagnostic flexible bronchoscopy procedures performed in Japan in 2010, the complication rate ranged from 0.15% to 2.06%, and the mortality rate was 0.004%.

We here present an unusual autopsy case of asphyxia caused by uncontrolled hemorrhage following TBLB.

Case Report

A 64-year-old woman was brought to the hospital's Emergency Department with a high fever. Chest radiographs showed ground glass opacities (GGO) in the lower right lung and these were confirmed by a chest CT scan (Figure 1A). Based on her physical examination, laboratory and imaging examinations, she was diagnosed with pneumonia and hospitalized. Her medical history included partial thyroidectomy for tumor. One week before admission, she had been prescribed steroids for cough variant asthma, with no improvement. A second CT scan showed slight worsening of the GGOs (Figure 1B). On day 3 of her hospitalization, she underwent flexible bronchoscopy to determine why her pneumonia was not resolving. TBLB was performed under fluoroscopic guidance. At first, TBLB was performed through the right B8 without critical problem. After that, the doctor examined the right upper lobe because of diffuse infiltrative shadow throughout the lungs. When TBLB was performed through the right B2b, slight hemorrhage from the biopsy site was observed and the bronchoscope wedged into the hemorrhaging bronchus with cold water until hemostasis had been

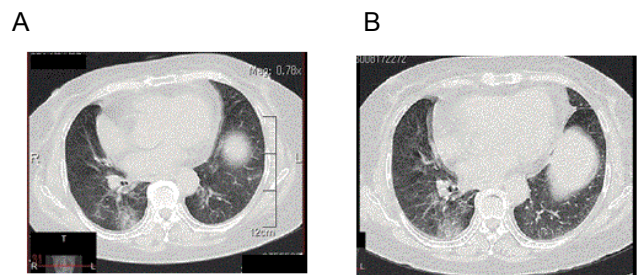


Figure 1: Chest CT scan image showing diffuse GGO in the right lower lobe on days 1 (A) and 3 (B) of the hospital admission.

achieved. An unsuccessful attempt was then made to obtain a sample through the right B2a; however, simple insertion of the bronchoscope caused hemorrhage from this bronchus, which was stopped by wedging the bronchoscope into the B2a. While attempts were being made to complete the bronchoscopy 20 minutes after its commencement, her blood pressure dropped significantly and hemorrhage prevented further visualization of the affected bronchus. The bronchoscope was removed and an unsuccessful attempt made to intubate the trachea. 30 minutes after the start of bronchoscopy, cardiopulmonary arrest occurred and she was given cardiac compression. 90 minutes after the start of bronchoscopy, an airway was finally established by performance of an emergency tracheostomy. 140 minutes after the start of bronchoscopy, she died in spite of receiving intensive care.

At autopsy, a 0.3 cm wound with clotted blood was observed on the wall of the right posterior bronchus (B2b) at the point of TBLB (Figure 2A). Saline infused into the right bronchial artery leaked from the

*Corresponding author: Unuma K, Department of Forensic Medicine, Graduate School of Medical and Dental Sciences, Medical and Dental University, Tokyo 113-8519, Japan, Tel: +81-3-5803-5199; Fax: +81-3-5803-0128; Email: unumlegm@tmd.ac.jp

Received July 31, 2016; Accepted August 10, 2016; Published August 13, 2016

Citation: Watanabe M, Unuma K, Makino Y, Komatsu A, Yamada A, et al. (2016) An Autopsy Case of Asphyxia Caused by Uncontrolled Hemorrhage Following Transbronchial Lung Biopsy. J Clin Respir Dis Care 2: 117. doi: 10.4172/2472-1247.1000117

Copyright: © 2016 Watanabe M, et al. This is an open-access article distributed under the terms of the Creative Commons Attribution License, which permits unrestricted use, distribution, and reproduction in any medium, provided the original author and source are credited.

mucosal wound and adjacent bronchial artery (Figure 2B). The lungs (left: 640 g, right: 880 g) were moderately edematous and the lungs were filled with a large volume of blood. The lung was infiltrated with small numbers of neutrophilic cells and moderate numbers of mononuclear cells. There was mild alveolitis, bronchiolitis and bronchitis, but no evidence of eosinophilic cell infiltration, granulomatous formation, fibrotic change, or hyaline membranes. The heart (370 g) showed mild hypertrophy but no old or recent infarcts and the coronary arteries were normal. The liver was slight yellowish and microscopy revealed mild lipid deposition within liver cells without fibrosis or inflammation. There was no evidence of recurrence of the thyroid tumor. No other macroscopic or microscopic pathological changes were observed. No pneumonia-associated pathogens were found on culture of bronchial swab samples.

Discussion

We here present an unusual autopsy case of a woman who died from asphyxia cause by uncontrolled hemorrhage following TBLB. An autopsy showed a small wound with clotted blood on the wall of the right posterior bronchi (B2b) and adjacent bronchial artery, which was the point of transbronchial lung biopsy. The lungs were filled with a large volume of blood. Other organs showed no significant findings.

Soon after the introduction of flexible bronchoscopy, Suratt et al. reported a complication rate of about 0.3% and mortality rate of approximately 0.025% [3]. Studies from the 2000s [4,5] have reported complication rates of 1.08–6.6% and mortality rates of 0.02–0.045%. A large survey in Japan [2] found complication rates ranging from 0.15 to 2.06% and a mortality rate of 0.004%. Flexible bronchoscopy procedures are considered comparatively safe provided attention is paid to patient selection and the patient's medical history and clinical examination findings reviewed. Risk factors include medication (especially antiplatelet and anticoagulant agents), clinical history such as cancer, site of lung lesion, and nature of the procedure [2]. Hemorrhage is a major and unavoidable complication [2]. TBLB is usually performed under fluoroscopic guidance; however, small arteries cannot be directly visualized and the biopsy forceps must be pushed to the lung periphery. Because hemorrhage with TBLB cannot be avoided

completely, being familiar with its management is crucial. Techniques for managing hemorrhage during bronchoscopy [6] include (i) wedging a rigid bronchoscope into the hemorrhaging bronchus and using a hemostatic agent; (ii) tamponading the bleeding site with a balloon-tipped catheter; (iii) performing one-lung ventilation to prevent blood flowing into the other lung; and (iv) appropriately timed bronchial arterial embolization. The most important goal is to maintain adequate SpO₂ by ventilating the intact lung or performing cricothyroidotomy and tracheostomy.

Only a few cases of diagnostic bronchoscopy-associated deaths have been reported in Japan [2]. In one case, it was caused by brushing of a solitary lesion in a patient with suppurative pneumonia, other deaths were attributed to cerebral infarction caused by air emboli following forceps biopsy of a solitary lesion, aortic dissection following simple bronchoscopy for diffuse lesions, and acute exacerbation of interstitial pneumonia after endobronchial ultrasonography transbronchial needle aspiration of hilar lymph node. Since hemostasis techniques have been improving based on a great deal of experience, fatal case of hemorrhage due to TBLB have not been reported in recent years [2,4,5].

To our knowledge, there have been no detailed reports of deaths caused by direct arterial injury during TBLB, such as occurred in our case. Failure to rapidly establish an airway for oxygenation and ventilation was the key factor in our patient's death: early performance of cricothyroidotomy and tracheotomy and urgent transfer to another hospital may have prevented our patient's oxygen desaturation and death. Not maintaining hemostasis technique at effectual level, hemorrhage can be a cause of death following TBLB even today.

References

1. Ikeda S (1979) Recent progress in bronchofiberscopy. *J Jpn Bronchoesophagol Soc* 30: 63-77.
2. Asano F, Aoe M, Ohsaki Y, Okada Y, Sasada S, et al. (2012) Deaths and complications associated with respiratory endoscopy: A survey by the Japan Society for Respiratory Endoscopy in 2010. *Respirology* 17: 478-485.
3. Suratt PM, Smiddy JF, Cruber B (1976) Deaths and Complications Associated with Fiberoptic Bronchoscopy. *Chest* 69: 747-751.
4. Smyth CM, Stead RJ (2002) Survey of flexible fibreoptic bronchoscopy in the United Kingdom. *Eur Respir J* 19: 458-463.
5. Facciolo N, Patelli M, Gasparini S, Lazzari Agli L, Salio M, et al. (2009) Incidence of complications in bronchoscopy. Multicentre prospective study of 20,986 bronchoscopies. *Monaldi Arch Chest Dis* 71: 8-14.
6. Du Rand IA, Blaikley J, Booton R, Chaudhuri N, Gupta V, et al. (2013) British Thoracic Society guideline for dignostic flexoble bronchoscopy in adults. *Thorax* 68: i1-44.

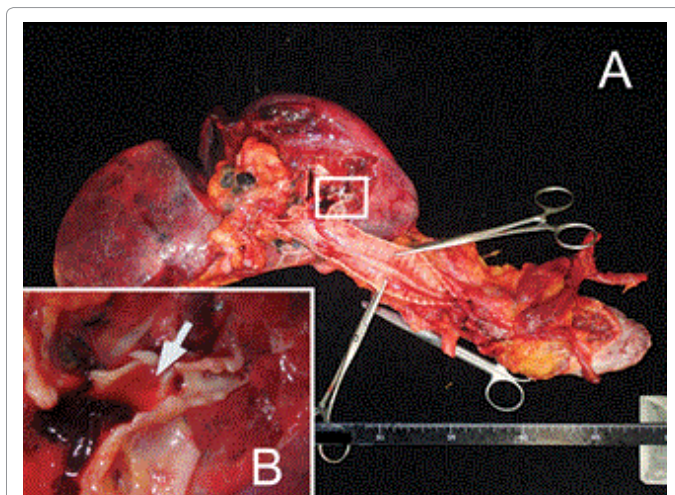


Figure 2: Macroscopic appearance of the right lung. (A) A wound with clotted blood was observed on the wall of right posterior bronchi (B2b), which was the point of TBLB. (B) Enlarged view. Infusion of saline from right bronchial artery resulted in leakage of saline from the mucosal wound and adjacent bronchial artery.