

## An Unusual Dermatological Presentation after a Trauma in a Twenty Four Months Old Girl

Ebadian M<sup>1\*</sup> and Senthilkumaran S<sup>2</sup>

<sup>1</sup>Department of Dermatology, Imperial College London, Charing Cross Hospital and Hammersmith Hospital, UK

<sup>2</sup>Department of Emergency and Critical Care, Erode Emergency Care Hospital, Erode, Tamil Nadu, India

### Introduction

Traumatic asphyxia (Perte's syndrome) is described as a condition where there is an intense compression of the thoracic cavity and this consequently will lead to venous backflow and increase in the right sided ventricular pressure. The backflow pressure that is caused here will lead to facial and neck congestion [1].

In the literature, traumatic asphyxia is usually described as a rare event in children and the incident is much higher in adults [2].

Our case describes a twenty four months old girl who was involved in a motor vehicle accident and despite not sustaining any organ injury she presented with multiple facial petechiae mainly on the face and the neck and bilateral conjunctival haemorrhage and subconjunctival oedema.

The dermatological manifestation such as skin petechiae as well as conjunctival bleeding and oedema persisted for 48 hours post trauma.

Fifteen days after discharge the skin petechiae and conjunctival haemorrhage had disappeared.

Not many junior doctors are familiar with the dermatological and ocular presentation of traumatic asphyxia and its occurrence in young children. Presenting this case will familiarise them with the presentation and management of this condition.

### Case Presentation

A 24 months old girl was brought to the emergency department after being trapped between the compound wall and the truck while a vehicle was being reversed. When she was transferred to the hospital, she was lethargic with Glasgow Coma Scale of 12 (E3V4M5). She was hemodynamically stable and maintaining adequate saturation with room air. The primary survey was unremarkable and the secondary survey revealed cyanosis on the face and multiple petechiae on the face and neck with haemorrhage of the bulbar conjunctiva in both eyes. Differential diagnoses at this level were Superior Vena Cava Syndrome and a base of skull fracture.

Her Computed tomography of head, chest, abdomen and pelvis was normal. Her blood test was all normal. She was monitored in the intensive care unit.

She was treated conservatively with mainly adequate oxygen supply to maintain good perfusion and increased oral fluid intake.

The patient was transferred from the intensive care unit to the ward after 3 hours of close monitoring. The GCS at this point was 15 however the dermatological changes on the face and the facial oedema persisted.

Her facial and thoracic petechiae started to fade away 48 hours post admission. She was followed up after 15 days where the petechial had disappeared and there was no evidence of conjunctival haemorrhage.

### Discussions and Conclusion

The definition of asphyxia is when there is deprivation of oxygen to the tissue [3]. Traumatic asphyxia is a rare condition that is caused

when there is a sudden trauma to the thorax area and this could present with facial and dermatological manifestation. Such signs include facial cyanosis, petechial haemorrhage that can manifest mainly on the face, neck, upper chest and upper limbs [4].

These are normally diffuse like purpuric petechiae which appears blue-red to blue-black that is non-blanchable but it starts to blanch over time. These lesions are more prominent on the eyelids and nose and around the lips. The discoloration and petechiae are often more prominent on the eyelids, nose, and lips [5].

The exact cause of the traumatic asphyxia is not yet clear but this has been described in the literature as sudden severe crush injury to the thorax and the diaphragm. This could be as a result of accident, seizures, persistent vomiting and even sexual abuse [6].

The mechanism is thought to be caused as a sudden increase of thorax pressure [7]. This is secondary to deep inspiration, closure of the glottis, thoracic and abdominal compression [8]. The increase in the pressure of the mediastinum is transmitted to the superior vena cava. This back pressure causes blood stasis in the neck vein and capillaries and ultimately their rupture producing petechial and haemorrhage under the skin, mucosal layer and conjunctiva.

Traumatic Asphyxia is usually described as a rare event in children and the incident is much higher in adults. This is thought to be due to the greater elasticity of the ribs in children [9].

When a child is presented to accident and emergency with signs and symptoms of traumatic asphyxia, this can be a quite daunting experience for both parents as well as junior doctors. One needs to realize as we have presented in our case report, traumatic asphyxia can also manifest in young children and for the junior doctors to have this diagnosis as part of their differentials when approaching such scenarios.

Once the more sinister causes has been ruled out patients can have a very good prognosis with adequate oxygen supply and conservative treatment (Figure 1 and 2).

### Learning points

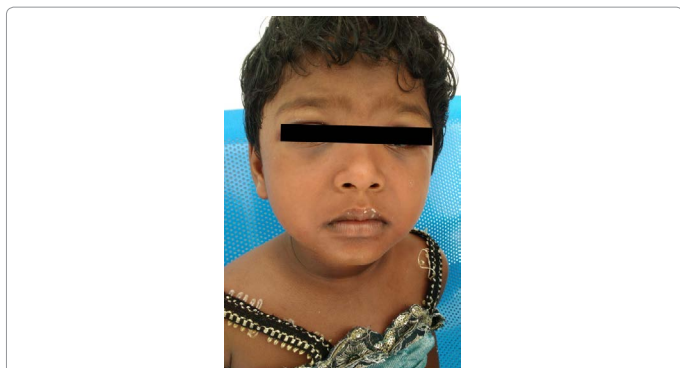- The most common cause of traumatic asphyxia is after motor vehicle accidents but can also be seen following seizure, asthma attack, severe vomiting and even after sexual abuse.

\*Corresponding author: Mona Ebadian, Department of Dermatology, Imperial College London, Charing Cross Hospital and Hammersmith Hospital, UK, Tel: +44203311 1234; E-mail: [monaebadian@nhs.net](mailto:monaebadian@nhs.net)

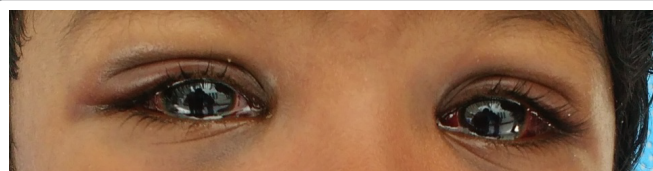
Received January 21, 2016; Accepted February 25, 2016; Published February 29, 2016

Citation: Ebadian M, Senthilkumaran S (2016) An Unusual Dermatological Presentation after a Trauma in a Twenty Four Months Old Girl. J Trauma Treat 5: 288. doi:10.4172/2167-1222.1000288

Copyright: © 2016 Ebadian M, et al. This is an open-access article distributed under the terms of the Creative Commons Attribution License, which permits unrestricted use, distribution, and reproduction in any medium, provided the original author and source are credited.



**Figure 1:** Facial cyanosis, petechial hemorrhage, more prominent on the cheeks and under the eye.



**Figure 2:** Bilateral conjunctival haemorrhage and subconjunctival edema.

- The main symptoms of traumatic asphyxia are: purpuric petechiae mainly on the upper chest, neck and the face as well as subconjunctival and facial oedema and conjunctival haemorrhage.
- This condition is more common in adults and this is mainly because of the greater elasticity of the ribs in children, however

as we have presented in our case report it can be seen in young children as well.

- The treatment is usually conservative with adequate oxygen supply to maintain good perfusion. The majority of the patients with traumatic asphyxia have good prognosis and the dermatological manifestations usually disappear within few days.

### Consent

Written informed consent was obtained from the patient for publication of this case report and accompanying images.

### References

1. Marx J, Hockberger R, Walls R (2013) Rosen's: Concepts and clinical practice (8th edn). Philadelphia, Saunders 435.
2. Hurtado TR, Della-Giustina DA (2003) Traumatic asphyxia in a 6-year old boy. *Pediatr Emerg Care* 19: 167-168.
3. Richards EC, Wallis ND (2005) Asphyxiation: a review. *Trauma* 7: 37-45.
4. Cenker E, Ozlem Y (2009) Traumatic asphyxia, a rare syndrome in trauma patients. *Int J Emerg Med* 2: 255-256.
5. Muthukrishan L, Raman R (2013) A child with traumatic asphyxia. *Indian Journal of Trauma and Emergency Pediatrics* 5: 13-15.
6. Montes-Tapia F, Barreto-Arroyo I, Cura-Esquivel I, Rodríguez-Taméz A, de la O-Cavazos M (2014) Traumatic asphyxia. *Paediatric Emergency Care* 30: 114-116.
7. Williams JS, Minken SL, Adams TJ (1968) Traumatic asphyxia, reappraised. *Ann Surg* 167: 384-392.
8. Sarihan H, Abes M, Akyazici R, Imamoglu LI (1997) Traumatic asphyxia in children. *J Cardiovasc Surg (Torino)* 38: 93-95.
9. Meller JL, Little AG, Shermeta DW (1984) Thoracic trauma in children. *Paediatrics* 74: 813-819.