

## ANXA7 Expression has Prognostic Impact for Patient Survival In Triple Negative Breast Cancers

Meera Srivastava<sup>1\*</sup>, Ofer Eidelman<sup>1</sup>, Lukas Bubendorf<sup>2</sup> and Harvey B. Pollard<sup>1</sup>

<sup>1</sup>Department of Anatomy, Physiology and Genetics, and Institute for Molecular Medicine, Uniformed Services University School of Medicine (USUHS), Bethesda, MD, 20814

<sup>2</sup>Institute for Pathology, University of Basel, Switzerland

### Abstract

Triple-negative breast cancers account for 10–17% of all breast carcinomas and there is considerable need for reliable prognostic markers to assist clinicians in making diagnostic and therapeutic management decisions. Altered *ANXA7* (a novel pro-apoptotic tumor suppressor gene located on chromosome 10q21) protein levels are associated with a tumor-prone phenotype in knockout mouse model and prognostically challenging aggressive forms of prostate and breast cancer. So far, information is not available regarding the association of patient survival and *ANXA7* expression in triple-negative breast cancers. Therefore, we used a retrospective prognostic tumor tissue microarray (TMA) technology in order to evaluate the *ANXA7* immunoreactivity as a possible diagnostic and/or prognostic marker of triple-negative breast cancer by immunoperoxidase assay using an *ANXA7* monoclonal antibody. We report here that the expression of *ANXA7* is significantly enhanced in triple-negative breast cancers and is associated with poor overall patient survival. We conclude that *ANXA7* may be a new prognostic markers or a target for improving the treatment efficiency of patients with triple-negative breast cancers.

**Keywords:** *ANXA7*; Triple-negative breast cancer; Survival; Prognosis

### Introduction

Breast cancer represents a heterogeneous group of tumors that are diverse in behavior, outcome, and response to therapy [1-3]. Currently, breast cancer patients are managed according to algorithms based on the clinical and histopathological parameters in conjunction with assessment of hormone receptor (estrogen and progesterone receptor) status and HER2 overexpression/gene amplification. While effective tailored therapies have been developed for patients with hormone receptor-positive or HER2+ disease, chemotherapy is the only modality of systemic therapy for patients with breast cancers lacking the expression of these markers (triple-negative breast cancers) [4]. Thus, the development of biologically informed systemic therapies and targeted therapies for triple-negative breast cancers is of paramount importance and may prove to be a challenging task, only achievable by understanding the complexity of this heterogeneous group of tumors. Although triple-negative breast cancers are reported to respond to neoadjuvant chemotherapy, survival of patients with such tumors is still poor and their management may therefore require a more aggressive alternative intervention [5]. Therefore, finding a reliable biomarker or a target that could be used to individualize both patient prognosis and therapy is essential for the prevention and cure of triple-negative breast cancers.

The finding of a novel tumor suppressor gene (*ANXA7*) in a chromosomal region with frequent mutations/deletions in human cancers raised important questions as to its use as a prognostic factor for the triple-negative breast cancer. Biochemically, we found that *ANXA7* codes for a membrane-associated, Ca<sup>2+</sup>-activated GTPase and is involved in exocytotic secretion [6-9]. In our work with the *Anxa7* knockout mouse we found that the nullizygous *Anxa7* (-/-) mutant is embryonically lethal and the *Anxa7* (+/-) animals developed profoundly increased frequency of tumors compared to the *Anxa7* (+/+) normal littermate controls. Tumor frequency is in the range of 20-50% of animals, becoming more accentuated with advancing age [10]. Consistently, using a prostate tissue microarray, we found

alterations of *ANXA7* protein expression in metastases and hormone insensitive local recurrent cancers. In addition, we found that allelic loss of the *ANXA7* gene occurs in over one third of primary carcinoma of the prostate and breast [11,12].

Further studies from our laboratory indicated that altered expression of *ANXA7* was associated with metastatic breast cancer with poor patient survival [13]. We have therefore hypothesized that *ANXA7* signaling might also play a role in triple-negative breast cancer. To test this hypothesis, we have used breast tissue microarrays containing approximately 71 biopsy specimens to ask whether the levels of expression of *ANXA7* might have predictive value for diagnosis and survival of these patients. The present study aims to show the expression of *ANXA7* in triple-negative breast cancer tissues and to elucidate its relationship to clinicopathological parameters and its impact on patient prognosis.

### Material and Methods

#### Patient characteristics

In our study, the conditions of 71 patients were diagnosed as triple-negative breast cancer patients and the archival specimens were printed on glass slides. This retrospective prognostic breast cancer tissue microarray consisted of the follow up data with tumor specific survival and treatment information. The age of the patients varied from 33 to 97 years, with a median age of 61 years. They were treated for

\*Corresponding author: Meera Srivastava, Ph.D Department of Anatomy and Cell Biology, USU School of Medicine, 4301 Jones Bridge Road, Bethesda MD, 20814, Tel :301-295-3204; Fax: 301-295-1786; E-mail: [msrivastava@usuhs.mil](mailto:msrivastava@usuhs.mil)

Received June 24, 2011; Accepted July 26, 2011; Published July 28, 2011

**Citation:** Srivastava M, Eidelman O, Bubendorf L, Pollard HB (2011) *ANXA7* Expression has Prognostic Impact for Patient Survival In Triple Negative Breast Cancers. J Mol Biomark Diagn 2:110. doi:10.4172/2155-9929.1000110

**Copyright:** © 2011 Srivastava M, et al. This is an open-access article distributed under the terms of the Creative Commons Attribution License, which permits unrestricted use, distribution, and reproduction in any medium, provided the original author and source are credited

primary breast cancer at the University Hospital in Basel (Switzerland), Womens Hospital Rheinfelden (Germany), and the Kreiskrankenhaus Lörrach (Germany) between 1985 and 1994. The median follow up time was 63.0 months (range 1 – 151). Formalin fixed, paraffin embedded tumor material was available from the Institute of Pathology, University of Basel. The pathologic stage, tumor diameter, and nodal status were obtained from the primary pathology reports. All slides from all tumors were reviewed to define the histologic grade according to Elston and Ellis (Gusterson et al., 1992) (BRE) and the histologic tumor type. Stage, grade and nodal status were strongly associated with tumor specific survival of our patients ( $p < 0.0001$  each).

### Tissue microarray construction

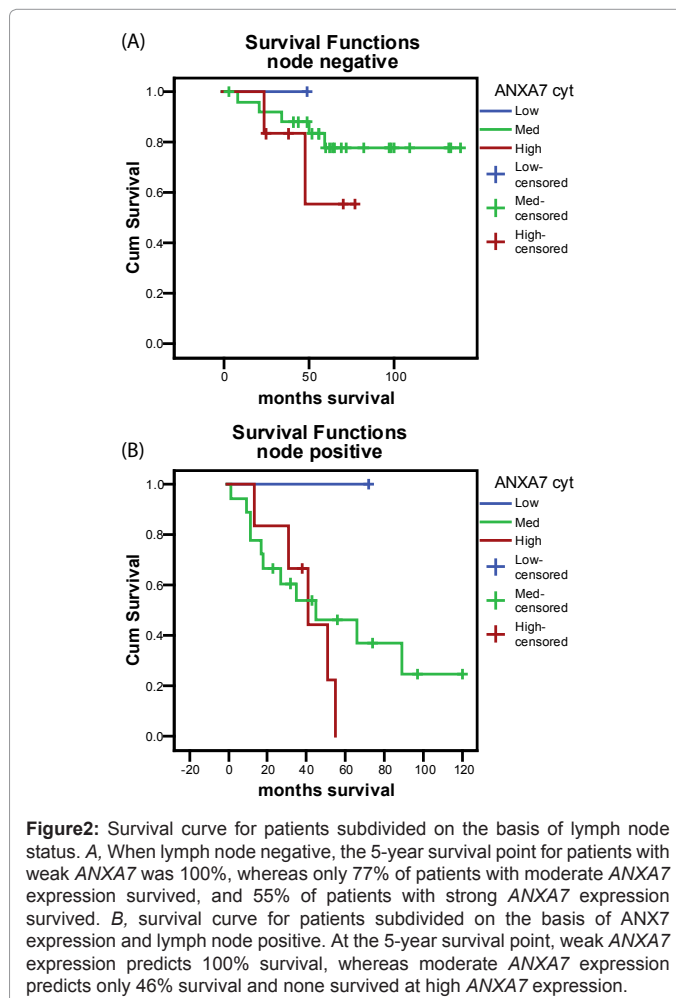
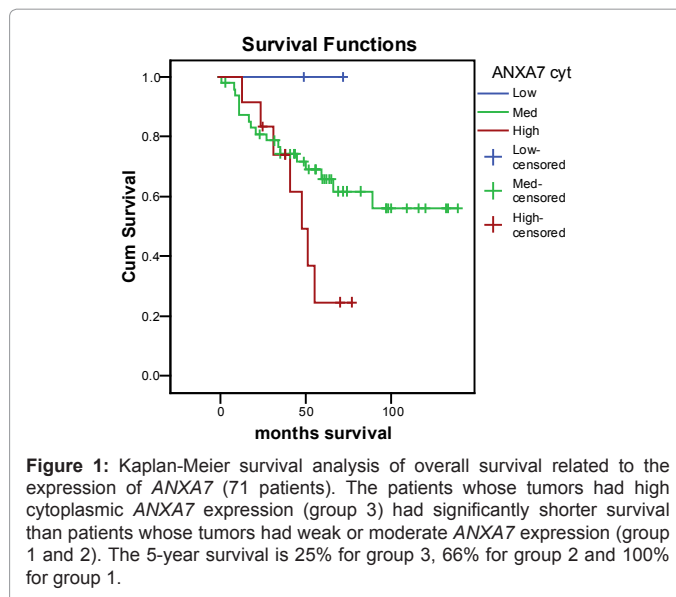
Tumor samples were arrayed as previously described [14]. Briefly, H&E-stained sections were made from each selected primary tumor block ("donor blocks") to define representative tumor regions. Tissue cylinders with a diameter of 0.6 mm were then punched from each "donor" block using a custom-made precision instrument (Beecher Instruments, Silver spring, MD) and brought into a recipient paraffin block eventually containing individual samples. The tissue microarray blocks were constructed in four replicas each containing samples from different regions of the donor tissues. One of these four samples was taken from the central part of the tumor and three from different peripheral areas. Four  $\mu\text{m}$  sections of the recipient blocks were then cut using an adhesive coated slide system (Instrumedics Inc., New Jersey) supporting the cohesion of the 0.6mm array elements on glass. One section from each of the four replica arrays was used for immunohistochemical analysis.

### Immunohistochemistry

Three conventional "large" sections from all tumors and three sections from each of the four different replica tumor tissue microarray blocks were used for immunostaining. The guidelines from the package insert were followed for each antibody. Standard indirect immunoperoxidase procedures (ABC-Elite, Vector Laboratories) in combination with monoclonal antibodies were used for detection of ANXA7 (1:1000, DAKO), Her-2 (Hercep test™ DAKO) p53 (DO-7, prediluted DAKO, Glostrup, Denmark), estrogen receptor (ER ID5, 1:1000, DAKO), and progesterone receptor (NCL-PGR, 1A6, 1:600, NOVOCASTRA Laboratories Ltd, Newcastle upon Tyne, United Kingdom). Tumors with known positivity were used as positive controls. The primary antibody was omitted for negative controls. These arrays have previously been tested for lack of interaction with irrelevant monoclonal antibodies. Scoring of the immunohistochemical staining followed the guidelines in the package insert using an objective at 10x magnification.

### Immunohistochemical Evaluation of ANXA7 Expression

The ANXA7 monoclonal antibody has been shown to recognize specifically ANXA7 and proved to be a useful reagent for immunohistochemical studies [11]. Human breast carcinomas with 71 specimens diagnosed as triple-negative breast cancer with follow-up data were examined for the expression of ANXA7 and their reactivity compared with normal human breast tissues. Three types of ANXA7 expression were detected in triple-negative breast cancer specimens. The first group showed weak ANXA7 expression (designated low), the second group showed moderate ANXA7 expression (designated medium), and the third group showed strong ANXA7 expression (designated high). The staining was nuclear and cytoplasmic as expected for a protein localized to the nucleus and cytoplasm. The



specificity of tissue staining was determined by the demonstration of negative staining by omitting primary antibody and with an irrelevant antibody.

Variable	Patients				Pearson p	Spearman r (p)
	n	ANX7 Low	Med.	High		
<b>Age</b>						
<60	41	0	30	11	0.016	-0.278 (0.019) *
≥60	30	3	24	3		
<b>pT</b>						
1	19	1	13	5	0.931	-0.046 (0.703)
2	39	2	30	7		
3	3	0	3	0		
4	9	0	7	2		
<b>pN</b>						
0	41	2	32	7	0.445	0.107 (0.389)
1	21	1	14	6		
2	5	0	4	1		
<b>BRE</b>						
1	2	0	2	0	0.807	-0.058 (0.666)
2	16	2	13	1		
3	43	0	32	11		
<b>P53</b>						
neg	38	2	28	8	0.955	-0.11 (0.927)
pos	33	1	26	6		
<b>Vessel infiltration</b>						
Not mentioned	58	3	46	9	0.049	0.236 (0.048)
yes	13	0	8	5		
<b>Lymph node metastasis</b>						
Node negative	40	2	31	7	0.420	0.102 (0.413)
Node positive	27	1	19	7		
all	67	3	50	14		
<b>5 year survival</b>						
Node negative	75.1%	100%	77.8%	55.6%		
Node positive	37.9	100%	46.2%	0		
all	60.1%	100%	65.9%	24.7%		

**Table 1:** The relationship between ANXA7 cytoplasmic expression levels and clinicopathologic factors in triple negative breast cancer samples.

### Statistical analysis

All data were analyzed by statistics software (SPSS 13.0 for Windows; SPSS, Inc). Survival time was measured in months from date of surgery until date of death or last follow-up. Survival analysis was performed using the Kaplan-Meier method and compared by the log-rank test. Prognostic relevance was evaluated by multivariate Cox proportional hazards regression analysis.  $P < 0.05$  was considered as significant.

### Results

#### Clinical correlation of ANXA7 Expression in triple-negative breast cancer patients

We used a prognostic breast cancer array containing 71 triple-negative breast cancer patient specimens with the retrospective follow-up of 105 months. ANXA7 expression was detected by immunohistochemistry and the presence of ANXA7 in each of these patients was correlated to survival parameters. Kaplan-Meier curves of cumulative survival in patients with low versus medium and high cytoplasmic ANXA7 expression shows a significant separation within 5 years of follow-up. Significantly, there is no change observed in nuclear ANXA7 staining in all the cases. Figure 1 illustrates the cumulative survival of 3 groups from the diagnosis of triple-negative breast cancer. The duration of survival was significantly shorter in patients

with strong cytoplasmic ANXA7 expression (group 3) compared with patients with weak ANXA7 expression (group 1) (25% versus 100% in 5 years). Similarly, with the increased ANXA7 expression in groups 1 and 2, the cumulative survival was decreased from 100% to 65%. When considered in a univariate analysis, that the patient group with weak ANXA7 have greater probability of survival, and that high cytoplasmic staining of ANXA7 is associated with lower probability of survival. These results indicate ANXA7 levels have considerable potential to be of practical use in routine assessment of triple-negative breast cancer patients.

#### Individual clinico-pathologic risk factor analysis

Parallel sections of the same specimens were investigated for alteration in the expression of p53, Her-2, ER and PR proteins [15]. Table 1 describes the composite univariate analysis of 71 triple-negative breast cancer patients in terms of classical clinical-pathologic risk factors including nodal status, tumor grade, stage, age along with the known prognostic factors such as p53 and lymphatic metastasis. Among the clinical parameters, the high cytoplasmic ANXA7 expression has a significant impact on the probability and rate of survival for lymph node negative patients. While 100% of the patients survived at weak ANXA7 expression, 77% survived at medium ANXA7 expression and only 55% at strong ANXA7 expression at the 5 year survival period (Figure 2a, Table 1). However, with lymph node positive patients, while 100% of the patients survived at weak ANXA7 expression, only 46% survived at medium ANXA7 expression and none of them survived at high cytoplasmic ANXA7 expression (Figure 2b, Table 1). Based on the analysis of all the parameters, it is evident that high cytoplasmic ANXA7 expression has a specific and moderate impact on the probability of survival for patients with varied lymph node status and BRE grade. Since the number of samples in each group was not sufficient, the statistical significance is not apparent.

### Discussion

Our study focused on the relationship between ANXA7 expression and human triple-negative breast cancer. Triple-negative breast cancer encompasses a heterogeneous group of tumors that show distinctive, but rather heterogeneous, pathological and clinical features and constitutes one of the most challenging groups of breast cancers to treat. Thus, the discovery of novel molecular targets for its diagnosis and treatment has the potential to improve the clinical strategy and outcome of patients with this disease. In this study, we investigated the high-risk group of breast cancer with the triple-negative phenotype that lacks the benefit of specific therapy and identified a central role for ANXA7 involvement in the progression of this aggressive triple-negative breast cancer. To our knowledge, this is the first study to demonstrate the role of ANXA7 expression in triple-negative breast cancer.

The selection of therapies for breast cancer today is based on prognostic features (chemotherapy, radiotherapy), hormone receptor status (hormonal therapy) and Her-2 status (trastuzumab therapy). Her-2 and p53 are tumor related proteins that have the potential to further improve individualization of patient management, by predicting response to chemotherapy, hormonal therapy and radiotherapy. The development of multiple organ hyperplasia and high incidence of spontaneous tumors in ANXA7 (+/-) knockout mice demonstrated that ANXA7 plays an important role in repressing tumor development. A significant relationship emerged between Her-2 and ANXA7. When Her-2 is negative, 66% of the patients with high ANXA7 expression can be distinguished from patients with no ANXA7 expression [12].

Our results in this study indicate that high cytoplasmic expression of *ANXA7* is associated with triple-negative breast cancer. In addition, our results show that high cytoplasmic expression of *ANXA7* is also associated with poor prognosis. Parallel sections of the same specimens were investigated for alteration in the expression of Her-2, p53, ER and PR. Our studies with a 105 months follow-up demonstrate that early stage patients with low cytoplasmic *ANXA7* expression have an excellent prognosis. Importantly with lymph node status with poor outcome, significant number of patients can be identified for high risk on the basis of their *ANXA7* expression, thus providing a powerful prognostic tool that can be validated and utilized in all the patients.

In conclusion, the present study shows the possibility of using *ANXA7* as both a clinically relevant indicator of disease progression and a prognostic biomarker for survival in the patients with triple-negative breast cancer. Based on the present data we therefore suggest that this new knowledge appears to operationally simplify prognosis for a significant fraction of the breast cancer population. For the triple-negative breast cancer patients so identified as being at particular risk, physicians can be alerted to the necessity of aggressive treatment. We conclude that if these data can be validated in a larger population of patients and in prospective studies with extensive follow-up, high cytoplasmic *ANXA7* expression could become an important biomarker for identifying triple-negative breast cancer patients at high risk, and is worthy of further exploration as a prognostic factor in survival. Finally, *ANXA7* may serve as a promising target for triple-negative breast cancer therapy.

## References

1. Reis-Filho JS, Simpson PT, Gale T, Lakhani SR (2005) The molecular genetics of breast cancer: the contribution of comparative genomic hybridization. *Pathol Res Pract* 201: 713–725.
2. Lacroix M, Toillon RA, Leclercq G (2004) Stable 'portrait' of breast tumors during progression: data from biology, pathology and genetics. *Endocr Relat Cancer* 11: 497–522.
3. Simpson PT, Reis-Filho JS, Gale T, Lakhani SR (2005) Molecular evolution of breast cancer. *J Pathol* 205: 248–254.
4. Rouzier R, Perou CM, Symmans WF, Ibrahim N, Cristofanilli M, et al. (2005) Breast cancer molecular subtypes respond differently to preoperative chemotherapy. *ClinCancer Res* 11: 5678–5685.
5. Carey LA, Dees EC, Sawyer L, Gatti L, Moore DT, et al. (2007) The triple negative paradox: primary tumor chemosensitivity of breast cancer subtypes. *ClinCancer Res* 13: 2329–2334.
6. Creutz CE, Pazoles CJ, Pollard HB (1978) Identification and Purification of an Adrenal Medullary Protein (Synexin) that Causes Calcium- dependent aggregation of isolated Chromaffin granules. *J Biol Chem* 253:2858-2866.
7. Creutz CE, Pazoles CJ, Pollard HB (1979) Self-Association of Synexin in the Presence of Calcium. Correlation with Synexin-induced membrane fusion and examination of the Structure of Synexin Aggregates. *J Biol Chem* 254: 553-558.
8. Raynal P, Pollard HB (1994) Annexins: the problem of assessing the biological role for a gene family of multifunctional calcium-and phospholipid-binding proteins. *Biochim Biophys Acta* 1197: 63-93.
9. Caohuy H, Srivastava M, Pollard HB (1996) Membrane fusion protein synexin (annexin VII) as a  $Ca^{2+}$ /GTP sensor in exocytotic secretion. *Proc Natl Acad Sci USA* 93:10797-10802.
10. Srivastava M, Glasman M, Leighton X, Naga S, Montagna C, et al. (2003) Haploinsufficiency of *Anx7* tumor suppressor gene and consequent genomic instability promotes tumorigenesis in the *Anx7*(+/-) mouse. *Proc Natl Acad Sci U S A* 100: 14287-14292.
11. Srivastava M, Bubendorf L, Srikantan V, Fossom L, Nolan L, et al. (2001) *ANX7*, a candidate tumor-suppressor gene for prostate cancer. *Proc Natl Acad Sci USA* 98:4575–4580.
12. Leighton X, Srikantan V, Pollard HB, Sukumar S, Srivastava M (2004) Significant allelic loss of *ANX7* region (10q21) in hormone receptor negative breast carcinomas. *Cancer Lett* 210: 239-244.
13. Srivastava M, Bubendorf L, Raffeld M, Bucher C, Torhorst J, et al. (2004) Prognostic impact of *ANX7*-GTPase in metastatic and *HER2*- negative breast cancer patients. *Clin Cancer Res* 10:2344-2350.
14. Kononen J, Bubendorf L, Kallioniemi A, Bärnlund M, Schraml P, et al. (1998) Tissue microarrays for high-throughput molecular profiling of tumor specimens. *Nat Med* 4: 844–847.
15. Torhorst J, Bucher C, Kononen J, Haas P, Zuber M, et al. (2001) Tissue microarrays for rapid linking of molecular changes to clinical endpoints. *Am J Pathol.* 159: 2249-2256.