

Decoy Cells due to Polyomavirus BK in the Urine Sediment of an Immunocompetent Patient

Jose Antonio Tesser Poloni*, Gabriel Godinho Pinto, Clotilde Druck Garcia and Alessandro C Pasqualotto

Federal University of Health Sciences of Porto Alegre, Brazil

Clinical Image

A 3-year-old girl with chronic kidney insufficiency (CKI) due to left kidney dysplasia and right multicystic kidney presented decoy cells due to polyomavirus BK (BKV) in the fresh and unstained urine sediment observed by phase-contrast microscopy (Figure 1).

BKV viruria and viremia were determined by a commercial qPCR kit (Nanogen, Italy) resulting in 3.3 billion and 2 viral copies/mL respectively. The patient was not receiving corticosteroid therapy and the total white blood cell count was 7,390/ μ L which 3,843/ μ L was lymphocytes revealing an apparent normal immune system.

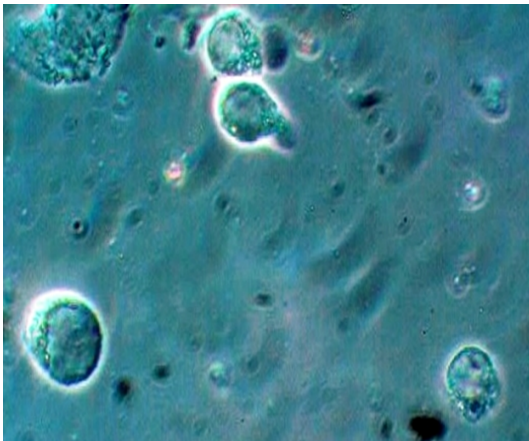


Figure 1: Fresh and unstained urine sediment. Phase contrast microscopy. Original magnification 400x.

There are few reports of decoy cells and/or polyomaviruses in the urine of immunocompetent individuals. Chiarinotti et al. [1] presented the case of a 31 year-old man historically known to have hemorrhagic cystitis and persistent microscopic hematuria who was diagnosed with polyomavirus reactivation by the presence of decoy cells in the urine cytology. The diagnosis was confirmed by n-PCR showing a polyomavirus JC type infection [1]. Breuer et al. [2] presented a case of infectious mononucleosis attended with transient asymptomatic BKV manifestation in the urine of an immunocompetent caucasian boy without kidney dysfunction [2] and Filler et al. [3] presented the case of a 10 year-old boy with acute lymphatic leukemia who presented with non-oliguric hypertensive acute kidney injury at the 12th maintenance cycle of his chemotherapy. The workup supported the clear diagnosis of BK virus nephropathy with tubulointerstitial changes [3].

According to the information available on these previous reports, our case shows that BKV reactivation can also be observed in immunocompetent patients. Since there was a known history of CKI and the BKV reactivation can represent an important cause of severe kidney injury, the premature detection of decoy cells during routine urinalysis may be a useful and inexpensive first step diagnostic tool.

References

1. Chiarinotti D, Ruva CE, David P, Capurro F, Brustia M, et al. (2002) [Polyomavirus infection in an immunocompetent patient and literature overview]. *G Ital Nefrol* 19: 74-78.
2. Breuer C, Hinsch A, Hiort J, Oh J, Hirsch HH, et al. (2014) Co-incident BK and Epstein-Barr virus replication in a 3-year-old immunocompetent boy. *Clin Nephrol* 82: 278-282.
3. Filler G, Licht C, Haig A (2013) Native kidney BK virus nephropathy associated with acute lymphocytic leukemia. *Pediatr Nephrol* 28: 979-981.

*Corresponding author: Jose Antonio Tesser Poloni, Federal University of Health Sciences of Porto Alegre, Porto, 90670-160, Brazil, Tel: +55-51-99689730; Fax: +55-51-32148090; E-mail: jatpoloni@yahoo.com.br

Received April 18, 2015; Accepted April 20, 2015; Published April 22, 2015

Citation: Poloni JAT, Pinto GG, Garcia CD, Pasqualotto AC (2015) Decoy Cells due to Polyomavirus BK in the Urine Sediment of an Immunocompetent Patient. *J Clin Case Rep* 5: i109. doi:10.4172/2165-7920.1000i109

Copyright: © 2015 Poloni JAT, et al. This is an open-access article distributed under the terms of the Creative Commons Attribution License, which permits unrestricted use, distribution, and reproduction in any medium, provided the original author and source are credited.