

# Dissecans Esophagitis of Probable Fungal Etiology: A Case Report

Manuella Candido Bastos<sup>1\*</sup>, Ketlin Batista de Moraes Mendes<sup>2</sup>, Cristhiany Ragnini Oliveira<sup>3</sup>, Andre Nazario de Oliveira<sup>3</sup> and Guilherme Eler de Almeida<sup>3</sup>

<sup>1</sup>Department of Gastroenterology, Institute of the Digestive System/Vilhena (RO), Rondonia, Brasil

<sup>2</sup>Department of Gastroenterology, Hospital University Getulio Vargas /Manaus (AM), Amazonas, Brasil

<sup>3</sup>Clinical & Medical Department, Regional Hospital of Cacoal/Cacoal (RO), Rondonia, Brasil

## Abstract

Dissecting esophagitis is a rare and benign form of chronic esophagitis, of diverse etiology, characterized by a typically whitish mucosa, with or without bleeding and presence of vertical circumferential fissures and cracks at endoscopy. Next, list a case of a young adult individual, who had a diagnosis of EDS with endoscopic diagnosis of EDS with probable cause of infection associated with loss of sub mucosal vascular component. After the diagnosis was made, therapeutic intervention was effectively possible.

Keywords: Palavras Chave • Chronic Esophagitis • Epigastralgia

## Introduction

Esophagitis Dissecans (EDS) is a rare form of chronic esophagitis, distinguished by typically whitened mucosa with or without bleeding and the feature of cracks and vertical circle. In 1997, Ponsot and his associates suggested the name of "Chronic Esophagitis Dissecans" and ever since, few cases were described in the literature [1]. The clinical history can unfold emetic episodes or regurgitation of the gastro-intestinal substance [2]. EDS is known for being a benign disease which might be associated to drug therapy, just as non-steroidal anti-inflammatory drugs, autoimmune dermatoses, inflammatory bowel diseases and idiopathic causes [3], besides infectious agentes as fungus and bacteria that might be observed in biopsies and that might be involved in the disease's pathogenesis [4]. Currently Upper Digestive Endoscopy (UDE) is the main tool for the early EDS diagnosis. Furthermore, the author reports a case of a young adult individual, previously salutar with no comorbidity who presented na EDS diagnosis within its probable cause associated to the loss of vascular sub mucous component.

## Case Report

The patient, a 30-year-old male seeks medical care reporting long-term burning epigastralgia and the recent worsening of the pain intensity and stress increase. The patient denies feeling bowel constipation, effort for evacuating or haematochezia. The patient also denies fever, vomit, weight loss or arthralgias. His physical exams didn't attest skin lesions, lymph nodes enlargement or any other abnormalities. In the past even without endoscopic or lab diagnosis he has self-medicated in order to treat *Helicobacter pylori*. In childhood he was diagnosed with Hepatitis B at 11 years old and malaria at 12. In his family history the author's attention is drawn to several cases of malignant neoplasia in first degree relatives: grandmothers who had lymphoma and breast cancer and grandfathers who had prostate and lung cancer. By that moment an UDE was requested and it revealed mid third scaling off esophagitis with moderate distal third edematous component (Figure 1). Slight enanthematous antral

endoscopic gastritis with slight erosive component and elevated antrum (Figure 2).

At the moment, some corpus and gastric antrum biopsies were done with *Helicobacter pylori* research, alongside with serial biopsies from the proximal, medium and distal esophagus (Figure 3). The astral gastric portion presented results compatible with chronic gastritis with multifocal bowel metaplasia; therefore in gastric corpus the results were normal, besides the *Helicobacter pylori* research showing negative for both portions. The microscopic biopsies exam showed absence of dysplasia and magnitude in all the analyzed samples. Among the lab exams the biochemical and the hematological blood sample standards show no significant changes.

## Discussion

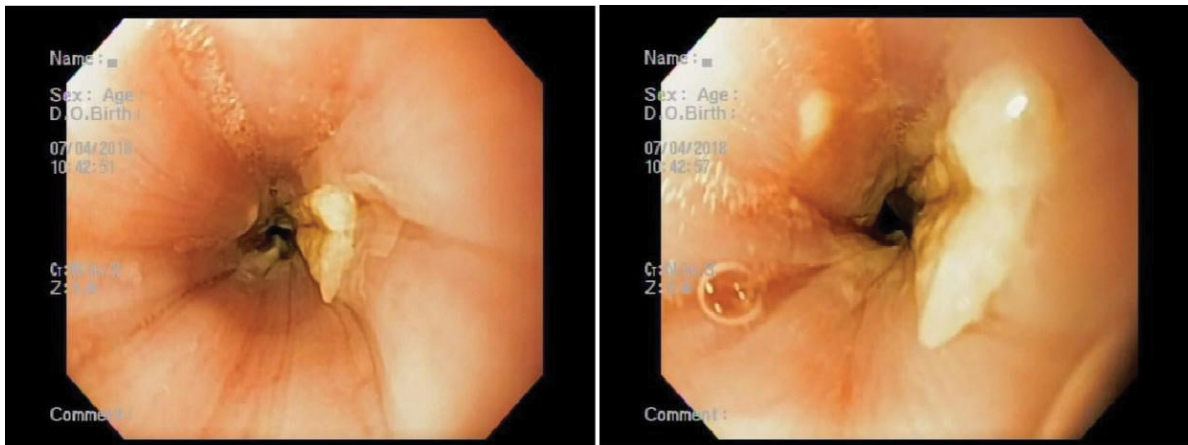
Some studies show that EDS is found in the absence of obvious predisposing conditions [4,5] as presented in the report above. Even though the pathogenesis remain unknown: some authors state that EDS represents a common squamous esophageal reaction among many types of aggressions and/or insults in many natures (physical, chemical, termic, immunological, for example), while some state this reaction is the hypothetical allergic topic response, even without the evidence of antigenic agents [6,7]. It is common in the outpatient care statements and complaints about dysphagia, odynophagia and reflux or even patients who show no symptoms. The UDE might bring to evidence the esophageal mucous inflammation like the ones found in esophagitis caused by *Candida sp.* Like the ones found on the case above which might lead to inaccurate results.

## Conclusion

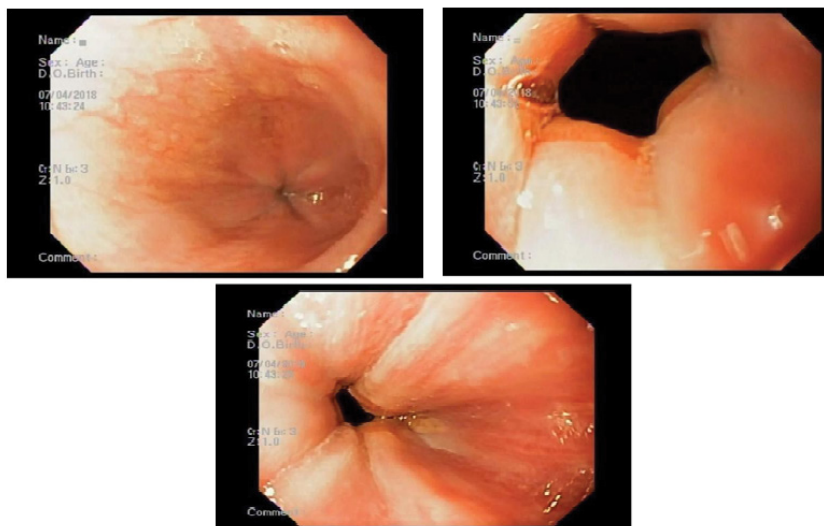
Our results obtained by UDE were consistent with EDS so the chosen course of treatment was Pantoprazole 40 mg/day orally administered for 15 days, Fluconazole 100mg/day orally administered and Nistatine oral suspension 100.000 U/ml mouth rinse with 4 ml from 6 to 6 hours, both for a week. The control UDE showed a complete normalization of the esophagitis, as long as new biopsies with the absence of eosinophil's and slight chronic esophagitiis. Even though the UDE shows esophagitis and scaling-off process, the clinic course is conducive and the complete remission of the inflammatory aspect of the mucosa is hit in short to medium term according to the chosen treatment described above, for example. The literature suggests EDS is a benign condition and the inflammatory process remission might be obtained through the combination of proton bomb inhibitors and the suspension of causing, suspicious or precipitant meds. When associated to bullous dermatoses, EDS treatment also includes the same interventions that might associate corticotherapy to the mucous healing.

\*Address for Correspondence: Bastos MC, Department of Gastroenterology, Institute of the Digestive System/Vilhena (RO), Rondonia, Brasil, E-mail: manucaabastos@gmail.com

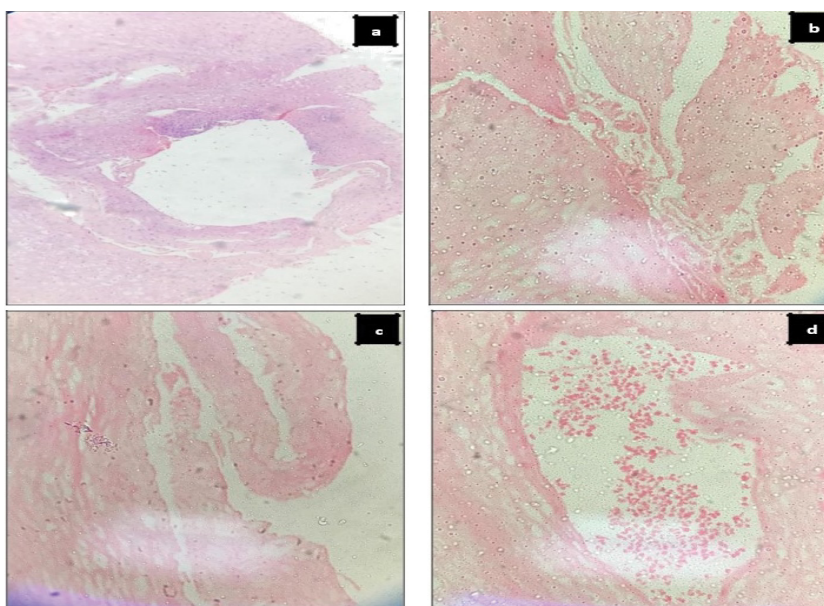
Copyright: © 2020 Bastos MC, et al. This is an open-access article distributed under the terms of the Creative Commons Attribution License, which permits unrestricted use, distribution, and reproduction in any medium, provided the original author and source are credited.



**Figure 1.** Medium esophagus showing circle scaling-off tissue for 3 cm easily removable, besides downstream normal mucosa and distal esophagus with vascular submucosa palisade structure loss.



**Figure 2.** Gastric mucosa with diffuse antrum rash and small upper circle erosion with fibrina in its pre-pyloric center: Other structures show no endoscopic changes.



**Figure 3.** (a) The proximal esophagus biopsy shows columnar epitalization of distal esophagus (cardio-piloric regenerative standard mucosa, absence of bowel metaplasia). Biopsy of medium esophagus with chronic erosive esophagitis and focal neutrophils exocitosis. (b,c): Paraqueratosis focus with coating epithelium scaling off among numerous saprophytes organisms among which *Candida* sp hyphae and bacteria were observed. (b,d): Biopsy of distal esophagus showed microerosive chronic esophagitis, basal layer hyperplasia and superficial epithelium focal peeling.

---

## References

1. Philippe Ponsot, Georges Molas, Jean-Yves Scoazec and Philippe Ruzsiewicz, et al. "Chronic Esophagitis Dissecans: An Unrecognized Clinicopathologic Entity." *Gastrointest Endosc* 45 (1997): 38-45.
2. Wagner G.G. Cesar, M. M. Barrios, Celina W Maruta and Valeria Aoki, et al. "Oesophagitis Dissecans Superficialis: An Acute, Benign Phenomenon Associated with Pemphigus Vulgaris." *Clin Exp Dermatol* 34 (2009): 614.
3. Randy S. Longman, Helen Remotti and Peter H. Green. "Esophagitis dissecans superficialis." *Gastrointest Endosc* 74 (2011): 403-404.
4. Susanne W. Carmack, Roopa Vemulapalli, Stuart J. Spechler and Robert M. Genta. "Esophagitis Dissecans Superficialis: A Clinicopathologic Study of 12 Cases." *Am J Surg Pathol* 33 (2009): 1789-1794.
5. Pedro Cardoso Figueiredo, Pedro Pinto-Marques, Jorge O. Neta and João Freitas. "Esophagitis Dissecans Superficialis." *GE J Port Gastreterol* 21 (2014): 123-124.
6. Hokama Akira. "Esophagitis Dissecans Superficialis and Autoimmune Bullous Dermatoses: A Review." *World J Gastrointest Endosc* 2 (2010): 252-256.
7. Kamal K. Rawal. "A Rare Case of Esophagitis Dissecans Superficialis Sloughing Esophagitis." *Gastroenterol Hepatol Int J* 2 (2017): 12.

**How to cite this article:** Manuella Candido Bastos, Ketlin Batista de Moraes Mendes, Cristhiany Ragnini Oliveira, Andre Nazario de Oliveira and Guilherme Eler de Almeida. "Dissecans Esophgitis of Probable Fungal Etiology: A Case Report." *Clin Case Rep* 10 (2020): 1342