

Esophageal Perforation in a Patient with Right Aortic Arch and Permanent Pacemaker

Huining Liu*, Guang Yang, Peng Qie and Lijun Liu

Department of Thoracic Surgery, Hebei General Hospital, Shijiazhuang, P.R. China

Abstract

We here report a case of esophageal perforation at the first esophageal stenosis in a 73-year-old patient with right aortic arch and permanent pacemaker. Although treated with fasting, gastrointestinal decompression, anti-inflammation and fluid replacement etc., the symptom is not improved. So, surgery is taken to clean the mediastinum abscess and used mediastinal drainage under the thoracoscope. The patient was discharged on postoperative day 30. Multiple factors restrict the treatment plan of this disease. The most important points are early diagnosis, applicable operation scheme and efficient chest drainage.

Keywords: Esophageal perforation; Right aortic arch; Thoracoscope surgery

Introduction

Esophageal perforation is a surgical emergency associated with high morbidity and mortality rates. The mortality remains high, with a pooled mortality of 22% from a recent review of published series [1]. The 30-day mortality rate from esophageal perforation at a national level in England is 30.0% [2]. Although many treatment options have been explored, no single efficient strategy has been developed to date. Conservative, surgical or endoscopic treatment strategies are available to the treatment. The treatment of the disease is dependent on the cause and location of the injury, the diagnosis time, the underlying esophageal disease, and the delay between injury and initiation of treatment. Here we reported our therapeutical experience of a case with cervical esophageal perforation caused by foreign body ingestion. The patient has abnormal right aortic arch and permanent pacemaker installed.

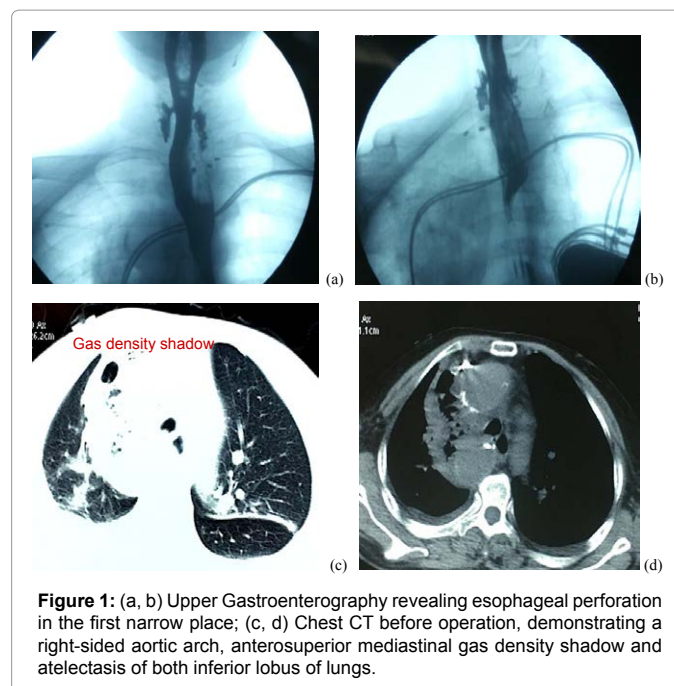
Case Report

A 73 years old female patient was hospitalized because of esophageal perforation. This patient experienced severe chest pain behind the body of sternum bone and high fever. The radiography showed esophageal perforation at the first esophageal stenosis, the heart with permanent pacemaker installed (Figures 1a and 1b). The chest CT showed a right-sided aortic arch, anterosuperior mediastinal gas density shadow and atelectasis of both inferior lobus of lungs (Figures 1c and 1d). Although treated with fasting, gastrointestinal decompression, anti-inflammation, and fluid replacement etc., the symptom was not improved; she therefore switched to our hospital. The physical examination showed no flare and subcutaneous emphysema in patient's neck. The gastroscopy showed local inflammatory lesion at the right-sided of esophagus within 23 cm from incisor. No obvious breach was observed. So, surgery is necessary to clean the mediastinum abscess and used mediastinal drainage under the thoracoscope. About 500 ml of purulent pleural effusion was removed. The superior border of the aortic arch was closed to the top of the pleural cavity, and all branches of the aortic blood vessels were not seen. Instead, the inner mediastinal abscess of descending aorta appeared at the azygos vein level (Figure 2). We fully separated the fibrous connective tissue of the abscess, removed the vomica, and then rinsed the thoracic cavity. A mediastinal drainage tube and an ordinary chest drainage tube were placed. The patient received gastric decompression, duodenal nutrition, and anti-inflammation treatment after the surgery. The esophageal imaging did after 12 days showed that the esophageal mucosa was intact. Then we removed the nasogastric feeding tube with patient eating small amount of liquid diet. The follow-up chest CT showed no obvious abnormality.

After removing the mediastinal drainage tube and observing for 2 days, the patient was discharged on postoperative day 30.

Discussion

Due to the anatomy of esophagus, it is easy to burst and perforate under stress and trauma. The esophageal perforation itself is already difficult to deal with, the condition will be more complicate when it is combined with the vascular dysplasia.



*Corresponding author: Huining Liu, Department of Thoracic Surgery, Hebei General Hospital, Shijiazhuang, P.R. China, Tel: +8613582187835; E-mail: 13582187835@163.com

Received December 10, 2016; Accepted January 19, 2017; Published January 25, 2017

Citation: Liu H, Yang G, Qie P, Liu L (2017) Esophageal Perforation in a Patient with Right Aortic Arch and Permanent Pacemaker. J Clin Case Rep 7: 913. doi: 10.4172/2165-7920.1000913

Copyright: © 2017 Liu H, et al. This is an open-access article distributed under the terms of the Creative Commons Attribution License, which permits unrestricted use, distribution, and reproduction in any medium, provided the original author and source are credited.

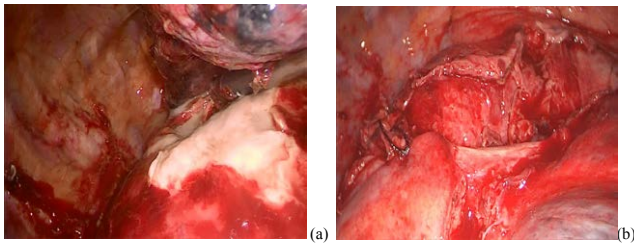


Figure 2: Intraoperative view (a) Mediastinal abscess of descending aorta appeared at the azygos vein level; (b) Mediastinal abscess was cleared.

Early diagnosis of esophageal perforation is the key to treat the disease on time and to reduce the mortality rate [3]. The mortality can reach 10% to 25% if esophageal perforation is managed within 24 h while it can rise to 40% to 60% when therapy is delayed beyond 48 h [4]. The principle of treatment for esophageal perforation is to prevent further spreading of infection, anti-inflammation and establish reasonable nutrition support. Therefore, extra attention should be given to the damage of surrounding tissue before treatment in addition to evaluate the severity of esophageal lesions.

The diagnosis of esophageal perforation. More than 50% of esophageal perforation were delayed in diagnosis and therapy [5]. The main reason for the delay in diagnosis of this patient is that her neck injury and infection is not obvious. The physical examination on the neck did not show any positive sign. When the patient shows the symptom of fever, the mediastinum infection is already formed. We didn't suggest the local hospital to use barium for esophageal radiography, because barium can infiltrate the mediastinum. Gastrografin should be used for esophageal radiography examination under this condition as its rapid absorption [6]. However, we should keep in mind that small esophageal perforation may show negative result with this method. It is therefore necessary to observe the damage area from multiple angles and positions.

The choice for surgical approach. Surgical intervention is an independent predictor for the mortality of esophageal perforation [2]. Choosing appropriate surgical operation is the key for therapy. We didn't use traditional neck incision and esophagus repairmen since this patient's esophageal injury has lasted for a long time although the neck infection was not severe, and since the anatomy of vessels in neck and chest has been changed by the right aortic arch. So, we adopted the method of thoracoscope mediastinum abscess incision drainage, and put two tubes for drainage in the chest and mediastinum.

The impact of right aortic arch on surgery. After opening the chest, the superior border of the arcus aortae was found to be close to the cupula pleurae. Based on above vascular contorts of the patient, the patient's condition belongs to type right aortic arch. The medial mediastinal abscess at the descending aorta azygos vein level showed the abscess parcel and aortic tissue edema. We opened the mediastinal pleura abscess with the ultrasonic knife, removed pus, and then gradually expand the area of clearing. During the operation, the superior vena cava must be protected, because it showed similar abscess parcel because of inflammation.

The nutrition support during perioperative period. In this case, we placed three-lumen feeding tubes (one is the stomach decompression tube and another two are duodenal nutrition tubes). The enteral nutrition support must be offered as soon as possible. The time of removing the nutrition tube is 5 days after starting oral food intake.

An efficient and favorable chest drainage is critical to the success of the surgery. After the operation, we used double tubes drainage with one mediastinal drainage and one ordinary chest drainage tubes. The mediastinal drainage tube should be placed in the 7th intercostal of the posterior axillary line with a depth of 25 cm. The epimere should be placed on the top of the mediastinum between the hilus of pulmonis and the top pleura with lateral holes on most of the drainage tubes. When the draining liquid shows stable, ordinary chest drainage should be removed. The mediastinal drainage tube can be removed when patient starts to eat normal food.

As the summary of the treatment experience, multiple factors restricted the treatment plan of this disease. Although the physical examination cannot show any positive signs, esophageal radiography examination might find the perforation when the gastrografin is used. Even in cases of esophageal perforation with abnormal anatomy, thoracoscope mediastinum abscess incision drainage can be recommended. Three-lumen feeding tubes might be advisable for rapid recovery. Based on our experience, mediastinal drainage is essential after surgery.

References

1. Hanif MZ, Li D, Jabeen S, Fan Q (2013) Endovascular repair penetrating aorto-esophageal foreign body injury. *Ann Thorac Surg* 96: 1457-1459.
2. Markar SR, Mackenzie H, Wiggins T, Askari A, Faiz O, et al. (2015) Management and outcomes of esophageal perforation: a national study of 2564 patients in England. *Am J Gastroenterol* 110: 1559-1566.
3. Reeder LB, DeFilippi VJ, Ferguson MK (1995) Current results of therapy for esophageal perforation. *Am J Surg* 169: 615-617.
4. Ashrafiyan H, Navarro-Sanchez A, Athanasiou T, Sherman DI, Isla A (2015) Thoracoscopic esophageal repair of a spontaneous barrett's ulcer perforation. *Ann Thorac Surg* 99: 331-333.
5. Mahmudlou R, Abdirad I, Ghasemi-Rad M (2011) Aggressive surgical treatment in late-diagnosed esophageal perforation: A report of 11 cases. *ISRN Surg* 2011: 868356.
6. Brinster CJ, Singhal S, Lee L, Marshall MB, Kaiser LR, et al. (2004) Evolving options in the management of esophageal perforation. *Ann Thorac Surg* 77: 1475-1483.