

## Hypofractionated Stereotactic Radiotherapy for Orbital Metastases: A Case Report and Review of Literature

Blerina Resuli<sup>1\*</sup>, Roberto Lisi<sup>1</sup>, Francesca De Felice<sup>1</sup>, Daniela Musio<sup>1</sup> and Vincenzo Tombolini<sup>1,2</sup>

<sup>1</sup>Department of Radiotherapy, Policlinico Umberto I "Sapienza" University of Rome, Rome 00161, Italy

<sup>2</sup>Spencer-Lorillard Foundation, Rome 00161, Italy

\*Corresponding author: Blerina Resuli, Department of Radiotherapy, Policlinico Umberto I, Sapienza University of Rome, Viale Regina Elena 256, 00161, Rome Italy, Tel: +39 06 49973411; Fax: +39 06 49973411; E-mail: [b\\_resuli@hotmail.com](mailto:b_resuli@hotmail.com)

Rec date: Jul 10, 2014, Acc date: Aug 21, 2014, Pub date: Aug 23, 2014

Copyright: © 2014 Resuli B, et al. This is an open-access article distributed under the terms of the Creative Commons Attribution License, which permits unrestricted use, distribution, and reproduction in any medium, provided the original author and source are credited.

### Abstract

**Objective:** To evaluate the efficacy and clinical outcome of hypofractionated stereotactic radiotherapy (HSRT) in non-small-cell lung cancer (NSCLC) cancer patients with orbital metastasis.

**Case report:** A 61-year-old man was admitted to the hospital referring right ptosis and dry hacking cough. HSRT was performed for the orbital metastasis followed by chemotherapy with cisplatin (60 mg/m<sup>2</sup>) and pemetrexed (500 mg/m<sup>2</sup>) on day 1 every 21 days for 4 cycles and maintenance pemetrexed (500 mg/m<sup>2</sup>) on day 1 every 21 days. Control TC scan revealed a complete response of the orbital mass.

**Conclusion:** HSRT should be considered a valid therapeutic alternative in the management of selected patient with orbital metastases.

**Keywords:** Disease-free survival; Hypofraction; Orbital metastases; Stereotactic radiotherapy

### Introduction

The incidence of primary tumors that metastasize to the orbit is approximately 7% [1]. The most common malignant primary tumors in adults metastasizing to the orbital are breast cancer (42%), lung (11%), unknown primary (11%), prostate (8.3%), melanoma (5.2%), gastro-intestinal tract (4.4%) and kidney cancer (3.2%). Orbital metastases spread hematogenously, as there are no significant lymphatics in the orbit [2,3]. The median survival after diagnosis of orbital metastasis has been reported to be approximately 9 months. In 19% of the cases, there is no history of cancer when the patient presents ophthalmic symptoms. Unilateral ptosis due to orbital metastases is rarely the first sign of lung cancer.

Due to improvements in radiation oncology techniques, systemic therapy and oncologic management, patients suffering from metastatic cancer may live longer [4,5].

### Case Report

On September 2012, a 61-year-old man was admitted to the hospital referring right ptosis. He also referred dry hacking cough for the past 2 months. He had no weight loss, nausea or vomiting. His medical history was unremarkable and no previous cardiac or pulmonary events were reported. The patient underwent physical examination showing unilateral ptosis in the right eye and a normal left eye. The patient visual acuity was good. The total body CT scan showed a solid mass along the posterior lateral orbital wall, invading the bone wall measuring 2.5 x 1.7 cm, an irregularly shaped pulmonary mass measuring 5.7 x 2.3 cm in the apical and posterior section of the right superior lobe, with connection to the pleura with right paratracheal

and Baret's space lymph nodes involvement. The CT scan showed an oval mass with regular margins, greater than 5 mm in diameter, in the lateral arch of the right seventh rib. The bone scan confirmed the metastatic lesion of the right seventh rib. The 18F-FDG PET/CT images showed high uptake in the in the apical and posterior section of the right superior lobe (SUV max 13), paratracheal and Baret's space lymph nodes (SUV max 7), the posterior lateral orbital wall (SUV max 12) and the 5th lumbar vertebra (SUV max 3.6). Fiber optic bronchoscopy with transbronchial biopsy was performed. The needle biopsy showed adenocarcinoma with acinar growth pattern. The patient underwent ultrasound-guided fine needle aspiration biopsy of the orbital lesion that revealed metastatic adenocarcinoma of the lung. After the diagnosis of metastatic lung cancer on October 2012 HSRT was performed for the orbital metastasis. Stereotactic treatment was performed using a five noncoplanar converging arcs technique. The patient was immobilized using a tight thermoplastic stereotactic head mask. The immobilization system includes a mouthpiece and a patient-specific dental mold with the patient's upper palate impression and solid vacuum bonding with the hard palate. The patient was supine on the treatment table while the gantry moved through a given arc. Irradiation was performed with 6-MV photons from a linear accelerator using a stereotactic based system (Figure 1).

The prescribed dose at the isocenter was 24 Gy in three fractions per week (800 cGy per fraction). The location of organ at risks (OAR) significantly influences the treatment planning process and the prescribed dose. Dose volume parameters of each OAR (the minimal and maximal doses) were determined; details are shown in Table 1 [6].

Three days after HSRT the patient received chemotherapy with cisplatin (60 mg/m<sup>2</sup>) and pemetrexed (500 mg/m<sup>2</sup>) on day 1 every 21 days for 4 cycles. Pemetrexed (500 mg/m<sup>2</sup>) was continued as maintenance therapy every 21 days on day 1. After completion of the second cycle and approximately 60 days after HSRT the total body CT

scan showed a response of approximately 50% of the orbital lesion, measuring 1.1 x 1 cm and also reduction of the lung tumour lesion and lymph node metastases. No toxicity was reported after treatment and the patient compliance was very high. The patient showed improvement of ptosis.

A second total body CT scan, performed at the completion of the fourth cycle of platinum-based chemotherapy, showed a further reduction of the orbital metastasis, measuring 0.8 x 0,7 cm and further reduction of the lung tumour. The 18F-FDG PET/CT performed approximately four months after HSRT did not show any significant metabolic activity in the orbital lesion and a significant reduction in size and metabolic activity of the lung tumor (Figure 2).

Finally, the total body CT scan performed at six months from the HSRT showed complete response of the orbit. It revealed stable actinic outcomes at the posterior lateral orbital wall, with an osteolytic area of 8 mm with no sign of compressive effects on the surrounding anatomical structures (Figure 3). Stable orbital disease remains one year after the end of treatment but there was a disease progression in lung, right adrenal gland and bone metastases. No late adverse events were reported. After eleven months of treatment mean visual acuity remained identical. The patient remains in good health conditions at eleven month from HSRT treatment.

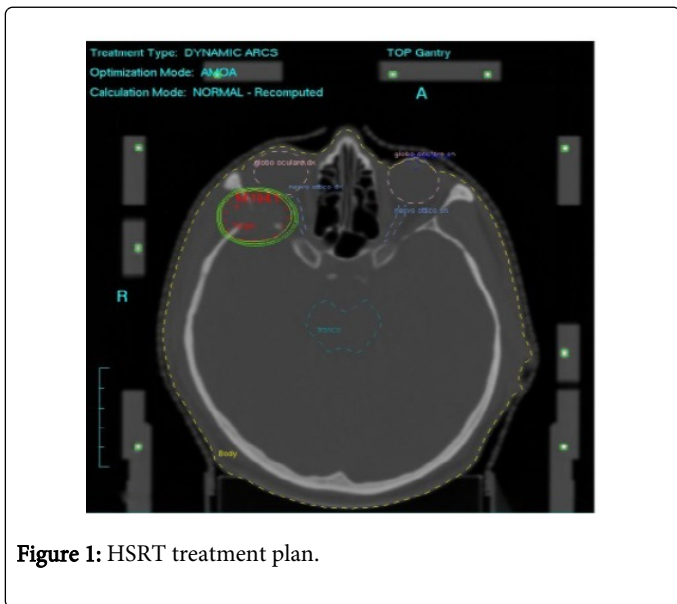


Figure 1: HSRT treatment plan.

OAR	Minimal Dose (cGy)	Maximal dose (cGy)
Optic chiasm	192	648
Right optic tract	1050	2232
Left optic tract	144	216
Brainstem	24	384
Right eye	168	2256
Left eye	0	168
Right crystalline	288	552
Left crystalline	24	120

Table 1: Dose volume parameters of each organ at risk (OAR).

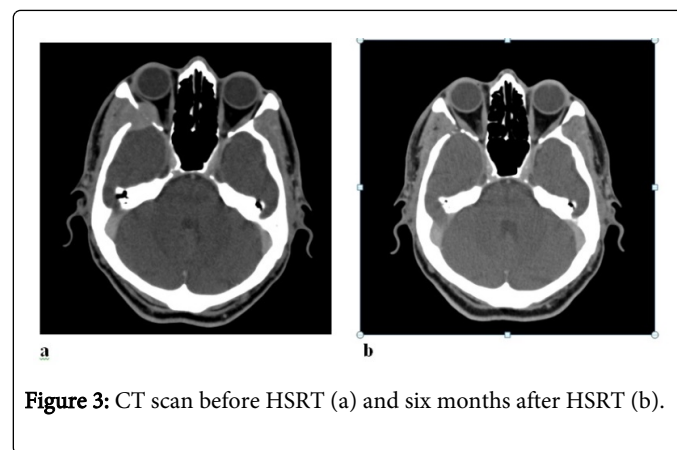


Figure 3: CT scan before HSRT (a) and six months after HSRT (b).

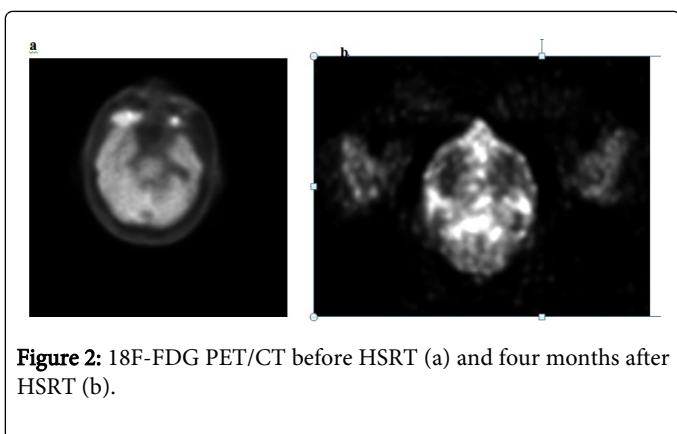


Figure 2: 18F-FDG PET/CT before HSRT (a) and four months after HSRT (b).

## Discussion

We present a single case of hypofractionated stereotactic radiotherapy (HSRT) delivered through a micro multi-leaf collimator linear accelerator on an orbital metastasis for a patient with metastatic non-small-cell lung cancer.

Most ocular metastases are asymptomatic and this may also explain the low incidence observed. Ocular symptoms could be an early event of metastasis from another site [7,8]. In our patient, ocular symptoms were probably due to the compression of the elevator and superior tarsal muscles.

This study presents a promising treatment option of orbital metastases with hypofractionated stereotactic radiotherapy. Tumor stabilization or decrease in size could be achieved in 87% of the lesions treated. This result is encouraging, especially regarding that stereotactic radiotherapy was the therapy of last resort, considering the high percentage of failed chemotherapy or conventional radiotherapy as well as the lacking access to surgical intervention.

Available treatment options of orbital metastasis are external beam radiotherapy, newer techniques like radiosurgery, stereotactic radiotherapy, and as well surgical resection [9]. In this case the chemotherapy alone is not a recommended treatment [10]. Metastatic peripherals lesions, such as those of the orbit are not, in fact, controlled in a satisfactory manner. No conclusion can be drawn from a single experience but we also underline that, due to limited number

of cases reported in the literature it is difficult to choose the best therapeutic option.

Nevertheless, our preliminary results appear to be very promising, considering the lack of other therapeutic options in this challenging case. Stereotactic radiotherapy was shown to be able to diminish intraorbital metastases originating from different primary tumors [11,12].

Aware of the fact that conclusions can not be drawn from a single experience, in agreement with other studies in the literature, we propose the HSRT as therapeutic alternative to consider, among other options in the management of selected patient with orbital metastases. HSRT ensures a good control of the lesion and symptoms without increased side effects. The excellent therapeutic result, in the case we present, may also be due to the short time between the end of radiotherapy and the start of chemotherapy.

Further studies should be initiated in order to compare the outcome of single fraction versus multisession radiotherapy and radiosurgery.

## Conclusion

In conclusion, when an orbital lesion is discovered, the differential diagnosis should include secondary metastases due to malignant tumors originated from distal organs [13]. This case highlights that orbital metastases can represent the first manifestation of metastatic lung cancer [14].

We propose HSRT as therapeutic alternative to consider, among other options in the management of selected patient with orbital metastases aware of the fact that further studies are needed to confirm this.

## Consent

The patient has given his informed consent for the case report to be published.

## Competing Interests

This manuscript has been read and approved by all the Authors. This paper is unique and is not under consideration by any other

publication and has not been published elsewhere. The Authors report no conflict of interests. The Authors confirm that they have permission to reproduce any copyrighted material.

## References

1. Macedo JE, Machado M, Araújo A, Angélico V, Lopes JM (2007) Orbital metastasis as a rare form of clinical presentation of non-small cell lung cancer. *J Thorac Oncol* 2: 166-167.
2. Valenzuela AA, Archibald CW, Fleming B, Ong L, O'Donnell B, et al. (2009) Orbital metastasis: clinical features, management and outcome. *Orbit* 28: 153-159.
3. Char DH, Miller T, Kroll S (1997) Orbital metastases: diagnosis and course. *Br J Ophthalmol* 81: 386-390.
4. Lachhab L, Fikri M, Aitbenhaddou EH, Arkha Y, Regragui W, et al. (2013) [Atypical metastatic sites for adenocarcinoma of the lung]. *J Fr Ophtalmol* 36: e23-26.
5. Marchetti M, Milanesi I, Falcone Ch, De Santis M, Fumagalli L, et al. (2011) Hypofractionated stereotactic radiotherapy for oligometastases in the brain: a single-institution experience. *Neurol Sci* 32: 393-399.
6. ICRU REPORT 60. Fundamental Quantities and Units for Ionizing Radiation. Issued: 30 December 1998. International Commission on Radiation Units and Measurements.
7. Velten IM, Gusek-Schneider GC, Tomandl B (2000) [Diplopia as first symptom of a bronchogenic carcinoma]. *Klin Monbl Augenheilkd* 217: 52-54.
8. Mori H, Maekawa N, Satoda N, Otsuka N, Sakai N, et al. (2003) [A case of primary lung cancer with initial symptoms due to orbital metastases]. *Nihon Kokyuki Gakkai Zasshi* 41: 19-24.
9. Klingenstein A, Kufeld M, Wowra B, Muacevic A, Fürweger C, et al. (2012) CyberKnife radiosurgery for the treatment of orbital metastases. *Technol Cancer Res Treat* 11: 433-439.
10. Wilson MW, Czechonska G, Finger PT, Rausen A, Hooper ME, et al. (2001) Chemotherapy for eye cancer. *Surv Ophthalmol* 45: 416-444.
11. Ng E, Ilse PF (2010) Orbital metastases. *Optometry* 81: 647-657.
12. Civit T, Colnat-Coulbois S, Freppel S (2010) [Orbital metastasis]. *Neurochirurgie* 56: 148-151.
13. Brady LW, O'Neill EA, Farber SH: Unusual sites of metastases. *Seminars Oncol* 1977;4:59-64. 8 Brady LW, O'Neill EA, Farber SH: Unusual sites of metastases. *Seminars Oncol* 1977;4:59-64.
14. Wang Y, Yang XJ, Li YY, Hei Y, Xiao LH (2008) [Diagnosis and management of orbital metastatic tumors]. *Zhonghua Yan Ke Za Zhi* 44: 687-690.