

## Incidental Fallopian Tube Adenocarcinoma Managed using Robotic Staging Surgery

Wang CW, Chen CH, Chen HH and Liu WM\*

Department of Obstetrics and Gynecology, School of Medicine, College of Medicine, Taipei Medical University, Taipei, Taiwan

### Abstract

Primary fallopian tube carcinoma is an uncommon gynecological malignancy. Management of primary fallopian tube carcinoma using a robotic-assisted approach is also rare. We have described here two cases of adenocarcinoma located in the fallopian tubes that were managed using robotic-assisted staging surgery, followed by subsequent serial chemotherapy. The surgical procedure consisted of a total hysterectomy, bilateral salpingo-oophorectomy, bilateral pelvi lymph node dissection, para-aortic lymph node dissection, appendectomy, omentectomy, peritoneal biopsies, and ascites cytology. After surgery, a test for CA-125 level and a computed tomography (CT) evaluation were conducted every 3 and 6 months, respectively. In Case I, the patient received 6 cycles of chemotherapy consisting of cisplatin and paclitaxel after surgery, and CA-125 level decreased from 55.9 U/mL to 9.5 U/mL over 6 months. At 16 months after surgery, a follow-up CT scan revealed no evidence of local recurrence. In Case II, the patient received 11 cycles of chemotherapy including cisplatin and paclitaxel, and CA-125 level decreased from 52.1 U/mL to 11.1 U/mL over 12 months. At 20 months after surgery, a follow-up CT scan revealed no evidence of local recurrence. In conclusion, robotic-assisted staging surgery is a feasible approach for treating incidentally located tumors in the fallopian tubes.

**Keywords:** Robotic surgery; Fallopian tube; Adenocarcinoma

### Introduction

Primary fallopian tube tumors, which are rare gynecological malignancies that account for 0.14%-1.8% of genital malignancy, mainly affect women aged 40-65 years [1]. Diagnosing primary fallopian tube tumors is challenging, and case reports involving tumors managed using robot-assisted staging surgery are rare. However, we have reported here two cases with favourable prognoses of primary fallopian tube tumors managed using robot-assisted staging surgery. The robotic-assisted procedures using three robotic arms were performed with the patient in the lithotomy position under general anesthesia. A uterine manipulator was put in place, and a pneumoperitoneum was obtained. For setting of the robotic surgery, a 12 mm camera port was set 6 cm above the umbilicus, and 8 mm trocars were set 8 to 10 cm caudal-lateral to the scope for the side arms at each side of the patient, respectively. We placed a fenestrated bipolar forcep in left arm for electrocoagulation and a monopolar curved scissor in right arm for simultaneous cutting and electro-cauterization. A manually operated accessory trocar, which was set at 6 to 8 cm caudal-lateral to the left arm, was placed for lymph node extraction.

The robotic arms were docked smoothly, and ascites was collected for cytological examination. The robotic surgery was performed with Endo Wrist instruments including monopolar curved scissors and fenestrated bipolar forceps. A grasper was used via the accessory port to assist in the surgical procedures. A survey of the operative field and evaluation of pelvic adhesion were performed. A frozen section of the suspected primary lesion was sent to confirm its malignancy prior to the main procedure. Surgical staging procedures including a total hysterectomy, bilateral salpingo-oophorectomy, bilateral pelvic retroperitoneal lymph node dissection, para-aortic lymph node dissection, appendectomy, omentectomy, peritoneal biopsies, and ascites cytology were performed. After the main procedures, the uterus was removed intact via the vagina, and transvaginal suturing was performed subsequently to close the vaginal cuff. After surgery, the dissected tissue was subjected to pathological examination.

### Case 1

A 49-year-old woman visited the author's clinic for abnormal vaginal discharge. She had not had a previous surgery or any family history of ovarian malignancy. She had menarche at the age of 13 and has had a regular menstrual cycle since then. She had given birth to two children and had never had an abortion. A transvaginal ultrasound performed in the clinic revealed ascites and a left adnexal heteroechoic mass, 7 × 3 cm. A P ap smear report revealed atypical glandular cells. On admission to the obstetrics and gynecology ward, an abdominal examination did not reveal anything significant; no abdominal palpable mass, abdominal pain or enlargement of lymph nodes were noted. A vaginal examination presented a free range of motion for the cervix with serosanguinous vaginal discharge but without palpable adnexal mass lesions. A pelvic CT scan showed an enhanced left soft tissue mass, 8 × 2 cm, in the left pelvic cavity. A left ovarian tumor was highly suspected.

Serum marker levels were obtained; CA-125 was 55.9 UI/mL (normal range is 0-35 UI/mL), and alpha-fetoprotein (AFP) and CA-199 were within the normal range. After informed consent, the robotic surgery was performed. A 7 × 3 cm left fallopian tube mass without exfoliation was resected. A section of the mass was then frozen and sent for examination to confirm its malignancy. Subsequent robotic-assisted

\*Corresponding author: Liu WM, Department of Obstetrics and Gynecology, School of Medicine, College of Medicine, Taipei Medical University, Taipei, Taiwan, Tel: 886-2-2737-2181; Fax: 886-2-6636-5192; E-mail: [weimin@tmu.edu.tw](mailto:weimin@tmu.edu.tw)

Received November 30, 2015; Accepted January 28, 2016; Published January 30, 2016

Citation: Wang CW, Chen CH, Chen HH, Liu WM (2016) Incidental Fallopian Tube Adenocarcinoma Managed using Robotic Staging Surgery. Adv Robot Autom 5: 138. doi: [10.4172/2168-9695.1000138](https://doi.org/10.4172/2168-9695.1000138)

Copyright: © 2016 Wang CW, et al. This is an open-access article distributed under the terms of the Creative Commons Attribution License, which permits unrestricted use, distribution, and reproduction in any medium, provided the original author and source are credited.

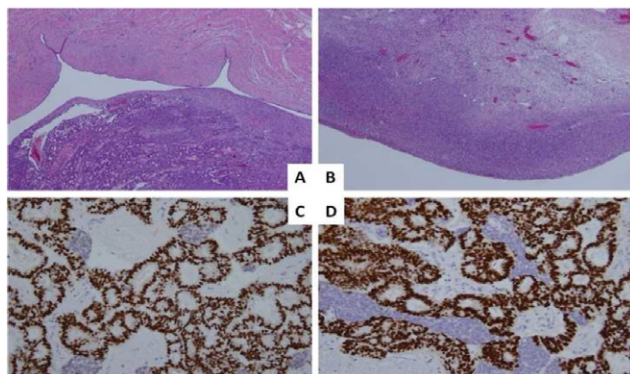
staging surgery, consisting of a careful inspection of the pelvic abdominal cavity, a total hysterectomy, bilateral salpingo-oophorectomy, bilateral pelvic lymph node dissection, para-aortic lymph node dissection, appendectomy, omentectomy, multiple peritoneal biopsies and ascites cytology, was performed. The operation procedure was uneventful and without complications. Intraoperative blood loss and the operation time were 200 mL and 3 hours and 55 minutes, respectively. A 7 × 3 cm mass was resected from the left fallopian tube. Bilateral ovary and uterus were grossly normal, and the length of hospital stay was four days. The histopathological examination revealed an endometrioid adenocarcinoma in the left fallopian tube. Careful examination showed no carcinoma on the left ovary surface. The immunohistochemical (IHC) stain for estrogen receptor (ER) and progesterone receptor (PR) were both positive and compatible with endometrioid adenocarcinoma (Figure 1). The extent of invasion was restricted to one tube within the serosa. There was suspicion of surgical spillage of the tumor, but there were no malignant cells found in the ascites; therefore FIGO stage reached IC.

Chemotherapy was planned for subsequent treatment. The patient received 6 cycles of chemotherapy (cisplatin/paclitaxel) after surgery. A CT scan of the chest, abdomen, and pelvis were negative for recurrence 6 months postoperation, during which the CA-125 level decreased from the preoperative 55.9 U/mL to 9.5 U/mL. No evidence of local recurrence was observed for 16 months after surgery.

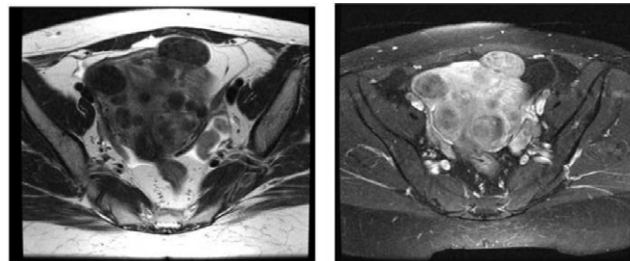
## Case 2

A 44-year-old woman visited the author's clinic for abnormal vaginal bleeding. She had not had a previous surgery and had no family history of ovarian malignancy. She had menarche at the age of 14. She had an irregular menstrual cycle, but no history of pregnancy. Before coming to the author's clinic, this patient visited other hospitals for abnormal vaginal bleeding. A 2 × 3 cm left heteroechoic adnexal mass was identified under transvaginal sonography, and enlarged para-aortic lymph nodes were noted on a CT scan, but no other obvious primary tumor sites were found. A CT guide biopsy of the para-aortic lymph node had been performed. The pathological report for the lymph node indicated adenocarcinoma.

On admission to the obstetrics and gynecology ward, a vaginal examination presented a free range of motion for the cervix, with no palpable adnexal mass lesions and no bloody vaginal discharge.



**Figure 1:** Histological examination for Case 1. (A) Left fallopian tube, endometrioid adenocarcinoma (40X). (B) Left ovary, no carcinoma (40X). (3) ER positive, consistent with endometrioid carcinoma (200X). (4) PR positive, consistent with endometrioid carcinoma (200X). (A and B, Hematoxylin and eosin; C and D, Immunohistochemistry).



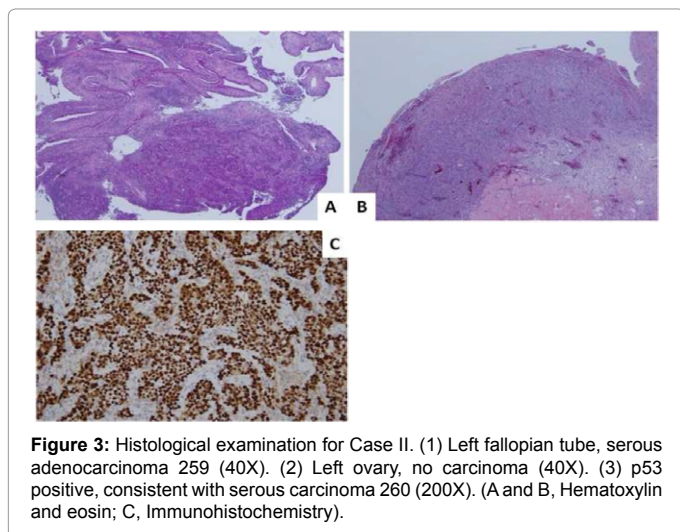
**Figure 2:** Magnetic resonance imaging (MRI) of Case 2. A 3 cm left adnexal low intensity mass noted on T2. Add on that enhanced in intensity on T1 with contrast. This mass is a soft tissue mass, but not fluid accumulation. Due to the fact that no other lesion was found on image scanning, this would be the potential primary lesion site.

However, a pelvic MRI revealed a lobular soft tissue lesion at the left adnexa (3.8 × 3.6 × 1.2 cm) (Figure 2), paraaortic lymphadenopathy, and mild ascites. Left adnexal malignancy was suspected. Serum marker levels were obtained; CA-125 was 52.1 UI/mL (normal value is 35 UI/mL) and alpha-fetoprotein (AFP) and CA-199 were within a normal range. After informed consent, robotic surgery was performed. On inspection of the pelvic abdominal cavity, the uterus and bilateral ovary were grossly normal, but a left fallopian mass, 3.6 × 1.2 cm, was noted. The mass was incised first and sent for examination to confirm its malignancy. The frozen section pathology revealed adenocarcinoma. Therefore, subsequent staging surgery, including a total hysterectomy, bilateral salpingo-oophorectomy, bilateral pelvic lymph node dissection, paraaortic lymph node dissection, appendectomy, omentectomy, and ascites cytology, was performed. The operation procedure was uneventful and without complications. Intraoperative blood loss was 100 mL, and the operation time was 4 hours and 15 minutes. On the day after the operation, the patient resumed normal intake and activity. Total hospital stay was 5 days.

The histopathological exam revealed serous adenocarcinoma in the left fallopian tube. No carcinoma was found on the left ovary. Immunohistochemical stain for p53 was positive and consistent with serous adenocarcinoma (Figure 3). Carcinoma was also noticed in the para-aortic lymph node, >2 cm; therefore FIGO stage reached IIIC. Chemotherapy was arranged for further treatment because of the advanced stage. After 6 cycles of chemotherapy including cisplatin and paclitaxel treatment, the serum level of CA-125 was above the normal range. Therefore, another 5 cycles of cisplatin and paclitaxel chemotherapy were performed with the patient's agreement. A CT scan of the chest, abdomen, and pelvis were negative for recurrence 6 months postoperatively. The CA-125 level decreased from a preoperative 52.1 U/mL to 11.1 U/mL during the 20 months of treatment. There was no evidence of local recurrence 20 months after the surgery. The patient will undergo further follow-up treatment.

## Discussion

Primary fallopian tube carcinoma (PFTC) is a rare malignancy. Renaud et al. first described fallopian tube malignancy in 1847 [2], and Orthmann et al. presented the first relevant case report in 1888 [3]. To diagnose a fallopian tumor, the main tumor must be confined to the tube with demonstrable carcinoma in situ, and changes must be apparent in the adjacent mucosa. The uterus and ovaries should be normal and not affected by the primary tumor. The classical Latzke's triad is comprised of intermittent serosanguinous vaginal discharge, pelvic pain secondary to tubal distension, and a pelvic mass. These



**Figure 3:** Histological examination for Case II. (1) Left fallopian tube, serous adenocarcinoma 259 (40X). (2) Left ovary, no carcinoma (40X). (3) p53 positive, consistent with serous carcinoma 260 (200X). (A and B, Hematoxylin and eosin; C, Immunohistochemistry).

symptoms are often nonspecific and only occur in 15% of patients [4]. In both cases in this report, there was vaginal discharge present but no pelvic pain or a pelvic mass, making diagnosis challenging.

Fallopian tube tumors play a crucial role in the origin of ovarian cancer [5,6]. The notion of this phenomenon came from PFTC as it was noted in patients with BRCA-1 and BRCA-2 mutations after risk-reducing salpingo-oophorectomy. Later Piek et al. hypothesized that most hereditary serous carcinomas originate from the epithelium of the fallopian tube [7]. These tubal epithelial cells spill onto the ovary surface, and then form ovarian cancer. In the present report, no further genetic testing was performed, but there was no family history of breast cancer or ovarian cancer in either case.

Imaging study may aid diagnosis in PFTC. Transvaginal ultrasound is regarded as a sensitive tool to diagnose pelvic masses. PFTC may appear as a sausage-shaped mass or a multilobular mass with a cog-and-wheel appearance on ultrasound [8]. In both of our cases, transvaginal ultrasound revealed an adnexa mass, giving the first clue of the location of the primary tumor. An MRI is considered a better tool than a CT scan or ultrasound for detecting tumor infiltration or extratubal tumors [9]. In Case 2, an MRI detected a highly suspicious left tubal mass, which was later confirmed intraoperatively.

Cytoreduction surgery is the gold standard and the most important prognostic factor for PFTC. The residual volume of the tumor after cytoreductive surgery inversely correlates with survival. According to a report represented by Wethington et al., a 5 year survival rate of PFTC for stage I to IV was 81%, 65%, 64%, and 36% [10], respectively. Although the best regimen for PFTC treatment is still unclear, the platinum-taxane base regimen is widely used in clinic for PFTC management [11]. In this report, the platinum-taxane base regimen is used for treatment of PFTC in both of our cases. There were different responses in these 2 cases. In Case 1, there was no evidence of tumor recurrence observed for at least 16 months after 6 cycles of cisplatin and paclitaxel treatment. In Case 2, stage IIIC, we administered an additional 5 cycles of platinum- taxane based chemotherapy due to a partial response during the first 6 cycles. Eventually, there was no evidence of recurrence in either patient.

The advantages of robotic surgery over laparoscopy for treatment of gynecological cancer include a lower volume of blood loss, a shorter operative time, a shorter length of hospital stays, and a clearer operative

field [12]. Although no randomized control trials were used to compare these 2 surgical techniques, controlled clinical trials support the use of robotic surgery in treating cervical cancer and endometrial cancer [13-15]. Nonetheless, the overall efficacy of robotic surgery in treating ovarian and fallopian tube tumors remains unknown. However, based on our clinical experience in managing ovarian cancer cases via robotic surgery, the surgical field, operation efficiency, surgical time, and blood loss are not inferior to those experienced during laparoscopy. There are no case reports which discuss fallopian tube tumors that were managed with robot-assisted surgery, especially by using three robotic arms; thus, our study is the first to report that robot-assisted staging surgery is a feasible approach for managing fallopian tube tumors.

In conclusion, it is unlikely that PFTC can be diagnosed preoperatively. Once suspected through hydrosalpinx or detection of an adnexal mass under transvaginal sonography, an MRI of the fallopian tube may further aid in diagnosis. Cytoreduction surgery, first with platinum-taxane based chemotherapy, remains the gold standard for treatment. Further randomized control trials will be needed to determine the outcome of robotic surgery for PFTC.

#### Acknowledgements

We would like to acknowledge the Taipei Medical University Hospital Cancer Center for the assistance in data collection. This work is granted by Ministry of Health and Welfare (MOHW103-TDU-B-212-113001) and the Ministry of Science and Technology (MOST 104-2320-B-038-063).

#### References

1. Kalampokas E, Kalampokas T, Tourontous I (2013) Primary fallopian tube carcinoma. *Eur J Obstet Gynecol Reprod Biol* 169: 155-161.
2. Renaud F, Ricci JV (1945) One hundred years of gynaecology. Philadelphia, Blakiston.
3. Orthmann EG (1888) Ueber carcinoma tubae. *Z Geburtshilfe Gynaecol* 15: 212.
4. Babu MR, Haji AG, Chitrathara K, Vijaykumar DK, Samanta J, et al. (2009) Primary transitional cell carcinoma of the fallopian tube in a premenopausal woman: A case report and review of literature. *Indian J Med Paediatr Oncol* 30: 35-38.
5. Erickson BK, Conner MG, Landen CN (2013) The role of the fallopian tube in the origin of ovarian cancer. *Am J Obstet Gynecol* 209: 409-414.
6. Reade CJ, McVey RM, Tone AA, Finlayson SJ, McAlpine JN, et al. (2014) The fallopian tube as the origin of high grade serous ovarian cancer: review of a paradigm shift. *J Obstet Gynaecol Cancer* 36: 133-140.
7. Piek JM, van Diest PJ, Zweemer RP, Jansen JW, Poort-Keesom RJ, et al. (2001) Dysplastic changes in prophylactically removed Fallopian tubes of women predisposed to developing ovarian cancer. *J Pathol* 195: 451-456.
8. Kol S, Gal D, Friedman M, Paldi E (1990) Preoperative diagnosis of fallopian tube carcinoma by transvaginal sonography and CA-125. *Gynecol Oncol* 37: 129-131.
9. Anthoulakis C, Nikoloudis N (2014) Pelvic MRI as the "gold standard" in the subsequent evaluation of ultrasound-indeterminate adnexal lesions: a systematic review. *Gynecol Oncol* 132: 661-668.
10. Wethington SL, Herzog TJ, Seshan VE, Bansal N, Schiff PB, et al. (2008) Improved survival for fallopian tube cancer: a comparison of clinical characteristics and outcome for primary fallopian tube and ovarian cancer. *Cancer* 113: 3298-3306.
11. Liu L, Xu X, Jia L, Wei M, Qian B, et al. (2015) Primary fallopian tube carcinoma-a retrospective analysis of 66 cases. *Eur J Gynaecol Oncol* 36: 161-167.
12. Gala RB, Margulies R, Steinberg A, Murphy M, Lukban J, et al. (2014) Systematic review of robotic surgery in gynecology: robotic techniques compared with laparoscopy and laparotomy. *J Minim Invasive Gynecol* 21: 353-361.
13. Verheijen R, Zweemer R (2012) Robotic surgery for gynaecologic cancer: an overview. *Curr Oncol Rep* 14: 544-549.

14. Chen CH, Chiu LH, Chang CW, Yen YK, Huang YH, et al. (2014) Comparing robotic surgery with conventional laparoscopy and laparotomy for cervical cancer management. *Int J Gynecol Cancer* 24: 1105-1111.
15. Chiou HY, Chiu LH, Chen CH, Yen YK, Chang CW, et al. (2015) Comparing robotic surgery with laparoscopy and laparotomy for endometrial cancer management: a cohort study. *Int J Surg* 13: 17-22.