

Multiorgan Involvement in a Complicated Case of Gum Abscess (Multiorgan Abscesses)

Sibel Ayik^{1*}, Ayse Dalli¹, Melek Cekic¹, Melda Apaydin² and Oktay Senoz³

¹Department of Chest Diseases, Izmir Katip Celebi University, Izmir, Turkey

²Department of Radiology, Izmir Katip Celebi University, Izmir, Turkey

³Department of Cardiology, Izmir Katip Celebi University, Izmir, Turkey

Abstract

Multi-organ abscesses which has high morbidity and mortality rates, usually develops after infective endocarditis. Clinical sepsicemia another rare cause of this condition. The pathogenic agents can be different and sometimes multiple. Clinical findings, laboratory and imaging results are important for diagnosis. The identification of causative pathogen and appropriate antibiotic treatment, and if necessary abscess drainage are very important for the treatment. We present a case with multipl colon, liver and lung abscesses which was a result of septicemia triggered by gum abscess. The causative agent has been found meticyllin resistant, coagulase negative *Staphylococcus cohnii ssp urealyticus*.

Keywords: Abscesses; Lung; Liver; Colon

Introduction

Pyogenic abscess occurs as a result of parenchyma tissue necrosis due to microorganisms and open cavity results the formation of localized suppurative lesion [1]. Multiorgan pyogenic abscesses rarely develops secondary to any focal origin without endocarditis [2]. Often, gum (periodontal) disease is the source of the bacteria that cause a lung abscesses. Primary focus in multiorgan abscesses' pathogens vary widely and can be multiple. Predisposing factors are immunosuppression, drug addiction and malignancy. The treatment is the appropriate use of antibiotics and abscess drainage [3].

We present a case with multiorgan (liver, lung, and sigmoid colon) abscesses originates from gum disease which is probably caused by anaerobic microbes and *staphylococcus cohn ssp urealyticum*.

Case Report

Fifty-year-old male patient who had engaged in veterinary medicine was admitted to our clinic with complaints of abdominal pain for two weeks, foul-smelling diarrhea and cough, sputum, chills, fever, night sweat for one week. The patient's posterior-anterior chest radiograph showed a subpleural cavitating lesion on the left upper zone (Figure 1). He was admitted to the pulmonology service for further investigation. Also he was a actively working veterenian and had no chronic illness. He had a history of smoking but did not use alcohol.

Physical examination; fever of 39°C, artery blood pressure (TA): 110/60 mmHg, pulse 100 beats / min, heart sounds were heard rhythmic without any additional sounds and murmurs. Lung examination was normal. There was mildly liver enlargement. Spleen was nonpalpable. Abdomen was nontender, bowel sounds hyperkinetic and a mass was felt on deep palpation in the suprapubic region. Orofaringial examination showed first molar mandibular tooth swelling and hyperemia compatible with the existing line abscess with intensive tooth decay. The other system examinations were normal. Laboratory parameters was showed in Table 1. Whole urine examination revealed normal.

The patient's stool culture, parasites examination was evaluated for two weeks of diarrhea and abdominal discomfort. The direct stool examination revealed abundant leukocytes and erythrocytes. There were no evidence of parasitic cysts and eggs. No aerobic fecal culture was isolated. The patient had purulent sputum. Aerobic growth and

hematocrit	29%
leukocyte count	39,300 / mm ³ (93% split)
hemoglobin	9.7g/dL
erythrocyte sedimentation rate	98 mm/h
Aspartataminotransferaz	142 U/L (N: 15-41 U / L)
alaninaminotransferaz	111 U/L (N: 17-45 U / L)
C-reactive protein	26.5 mg/dL (N=0.01-0.82)
procalcitonin: 1.7 ng/dL (N=0-0.1).	1.7 ng/dL (N=0-0.1)

Table 1: The patient's laboratory results before the treatment.

acid-fast bacilli were not detected in sputum using Erlich - Ziehl - Nielsen staining.

According to the patient's clinical findings as well as suspicious mass image in posterior-anterior chest X-ray in Figure 1 and lower abdominal palpable pathology, contrast enhanced thoracoabdominal computed tomography scan (CT) was obtained. There was a slightly irregular cavity on the left upper lobe of the lateral, subpleural region, 43 × 30 mm in size, lightly lobulated with smooth inner slightly irregular contour. There was no other lesion in the other lung areas (Figure 2A). There were ring enhanced hypodense lesions in the right and left lobes of the liver up to 3 cm in diameter (Figure 2B). There were sigmoid colon diverticulae also accompanied with sigmoid mesentery abscess (Figure 2C).

Moderate liver enlargement with peripherally echogenic, hypoechoic foci close to Vena Cava Inferior (VCI), compatible with abscesswere shown at abdominal ultrasound.

Due to the patient's symptoms and radiological findings, control fecal examinations were sent for re-evaluation. Control of stool revealed no evidence of parasitic cysts and eggs again. The serologic tests for

***Corresponding author:** Sibel Ayik, Department of Chest Diseases, Izmir Katip Celebi University, Turkey, Tel: +90 232 329 3535; E-mail: sibeloktem2000@gmail.com

Received June 17, 2015; **Accepted** July 16, 2015; **Published** July 18, 2015

Citation: Ayik S, Dalli A, Cekic M, Apaydin M, Senoz O (2015) Multiorgan Involvement in a Complicated Case of Gum Abscess (Multiorgan Abscesses). J Clin Case Rep S2: 003. doi:10.4172/2165-7920.S2-003

Copyright: © 2015 Ayik S, et al. This is an open-access article distributed under the terms of the Creative Commons Attribution License, which permits unrestricted use, distribution, and reproduction in any medium, provided the original author and source are credited.

Cyst Hidatic was negative. Brusella rose bengal test, antitoxoplasma kemilum sans test and hepatic viral parameters (HBsAg, hepatitis B infection, Anti-HCV, Anti-HIV, Anti-CMV) were negative as well.

There was no evidence of infective endocarditis such as vegetations during transthoracic echocardiography. Cardiac functions were within normal limits in cardiac examinations. In the febrile period of hospitalization, peripheral blood cultures from right and left brachial veins were taken in three sets, then cultures were repeated.

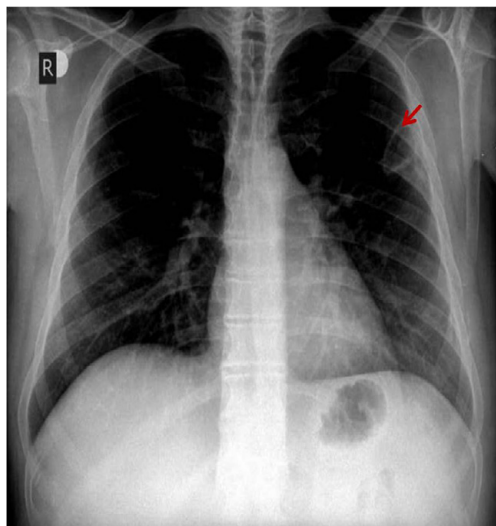


Figure 1: Posterior-anterior chest radiograph showed a subpleural cavitating lesion on the left upper zone.

During the hospitalization, Cefuroxime axetil (3 x 750 mg/IV) and metronidazol (4 x 500 mg/IV) were given empirically to patient. Due to the patients's persistent fever (in the high 39-40°C range) and clinical deterioration, the drugs were changed and meropenem (3x 1000 mg) and vancomycin (2 x 1000 mg) has been replaced. The patient's fever went down to normal levels 24 hour later also the chills, night sweats and diarrhea decreased. The infectious parameters were lessened soon. The liver abscess was consulted by radiology department whether to perform sampling. This procedure could not be done because of the lesions proximity to vena cava inferior and shrinkage related to the treatment. Blood cultures which was taken before starting antibiotics in febrile period had been found to be positive for methicillin resistant Staphylococcus spp urealyticus cohnii. No changes were made in the drugs as patient's had been receiving effective broad-spectrum antibiotics.

The patient's colonoscopy could not be done due to his unwillingness of the procedure.

The patients had control CT on day 16. of meropenem treatment, after the clinical complete improvement and without having any symptoms. The size of the lung abscess decreased to 24 x 12 mm (Figure 3A). The liver abscess had shrunk and there were fibrous like structure around them (Figure 3B). Also the abscess in the sigmoid colon was disappeared (Figure 3C).

Repeated blood cultures were negative, laboratory parameters was shown in Table 2; All the parametes showed normalized levels. Antibiotic therapy was continued as an oral therapy for an additional 3 weeks after parenteral route and ambulatory process completed 4 weeks. There were no complications and follow-up in the hospital were discharged healthy (Figure 4A-C).

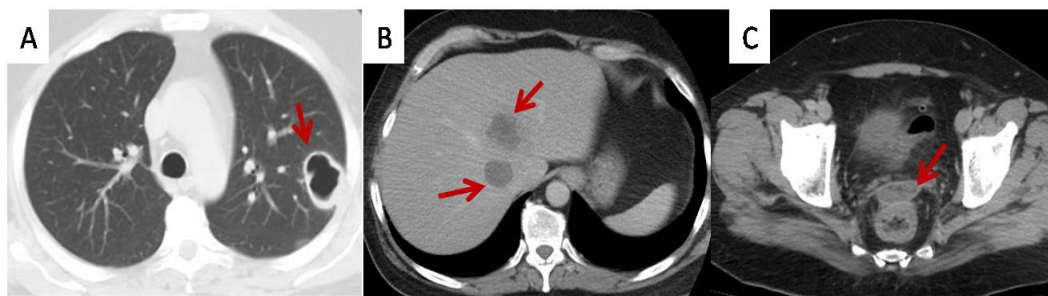


Figure 2: Before treatment on CT scan; A: Thorax CT scan: The lesion (lung abscess) is 43 x 30 mm in size before treatment. B: Upper Abdominal CT scan: Multiple liver abscesses in liver. C: Lower Abdominal CT scan: Sigmoid colon's abscess.

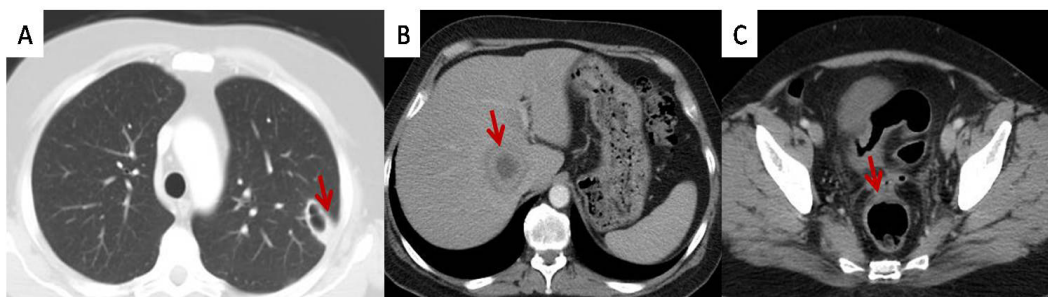


Figure 3: On day 16 of treatment; A: Thorax CT scan: Left upper lobe lung abscess was getting smaller after treatment. B: Upper Abdominal CT scan: The liver abscess had shrunk and there were fibrous like structure. C: Lower Abdominal CT scan: Substantially shrunke.

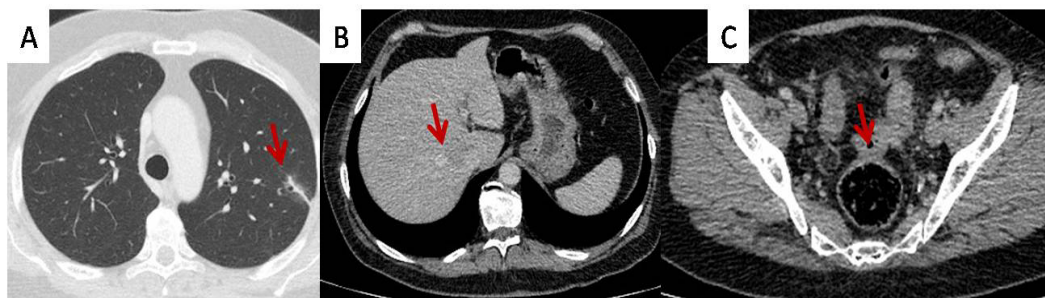


Figure 4: Post-treatment; A: Thorax CT scan: The abscess was completely healed but some fibrotic lung changes were seen at that area of left lung. B: Upper Abdominal CT scan: There were no sign of abscess in liver. C: Lower Abdominal CT scan: The sigmoid colon abscess.

hematocrit	33%
leukocyte count	9.500/mm ³
hemoglobin	10.6 g/dL
erythrocyte sedimentation rate	28 mm/h
aspartataminotransferaz	13 U/L (N: 15-41 U / L)
alaninaminotransferaz	11 U/L (N: 17-45 U / L)
C-reactive protein	3.8 mg/dL (N=0.01-0.82)
procalcitonin: 1.7 ng/dL (N=0-0.1).	0.12 ng/dL (N=0-0.1)

Table 2: The patient's laboratory results after the treatment.

Conclusion

Multiorgan pyogenic abscesses which are usually secondary to infective endocarditis or infected vascular complications of the mycotic aneurysms, rare infectious disease with serious clinical outcome. Artificial heart valves, the structure of degraded natural valves, congenital heart disease, immunosuppression, substance abuse, diabetes mellitus and malignancy may be predisposing factors for multiple organ abscesses [1,2].

Multiorgan pyogenic abscesses can spread to directly between adjacent tissue or to distant organs via sepsis, through the thoracic spread, through the bile-hepatik- aperture [3,4]. Yang et al. reported a case pyogenic lung abscess caused by septic pulmonary embolism [5].

In our case, there were multiorgan abscess as a result of gum abscess without infective endocarditis. The biggest protective factor for infective endocarditis development is normally developed cardiac structures which was confirmed by transthoracic echocardiography. Direct tissue infiltration was not considered for the abscesses due to the remote location of the lesions from each other. Septisemia was considered the cause.

Pyogenic multiorgan abscess usually shows a fulminant course. Due to the use of broad-spectrum antibiotics in recent years, increasing the quality of development and intensive care services and improvement of the imaging methods provides relatively positive results. But mortality and morbidity due to the seriousness of sepsisemia is high [6,7].

There was no predisposing factor in our case. The patient's clinical remained relatively lighter. The significant permanent damage to the tissue to disrupt the function did not occur in the involved organs. The patient's lack of comorbid pathology, young age and rapid respond early broad-spectrum antibiotics were the concluded the cause of the result.

Appropriate use of antibiotics is very important in effective treatment of pyogenic liver abscess. In the cases of, inadequate/failure of antibiotic therapy, life-threatening organ involvement

(etc. intracranial involvement), uncontrolled abscess focus surgical or percutaneous intervention is required [8]. Rapid diagnosis and initiation of broad-spectrum antibiotic treatment increases the chances of success are the most important factors.

According to the responsible pathogen primary focus of multiple organ abscesses varies enormously. Streptococci viridans, coagulase positive and negative staphylococci, Escherichiacol, Klebsiella pneumoniae, and Bacteroides fragilis can be isolated [7-10]. The multiple agents may be cause as well. While the sampling rate was around 80% of the abscess culture, the rate of blood culture isolate the factor is about 50% [10].

Empirical therapy should be selected according to the source of the abscess and underlying disease [11]. General empirical approach applied in the treatment protocol ampicillin-sulbactam/second-generation cephalosporins, and aminoglycosides and/or the combination of metronidazol [12-15]. Average treatment time is four weeks.

Antibiotics should be given intravenously during the first two weeks of treatment, then be administered orally [12-17]. In our case, after obtaining blood cultures in febrile period, cefuroxime axetil and metronidazole was started empirically. Combination of meropenem-vancomycin was started due to continued fever. Twenty-one days after oral treatment with outpatient parenteral antibiotic therapy was completed in four weeks.

Contrast-enhanced computed tomography (CT) is the gold standard method for the diagnosis of pyogenic abscess and sensitivity is close to 100%.

Ultrasonography (USG) is a cheap, widely available method for diagnostic evaluation of abdominal organs. Clinical and ultrasonographic co-evaluation is quite pathognomonic (greater than 90%) for diagnosing abdominal abscess. This procedure can be done in any stage of the disease due to non invasiveness and high sensitivity (90%) especially in good hands [4]. In our case diagnosis of multiple abscesses was made by contrast thoracoabdominal CT and liver abscesses were confirmed by abdominal ultrasound.

The most feared complication of mutiorgan abscess are permanent damage to the tissue disturbance function, sepsis, septic shock. Our case, was discharged from hospital monitoring progress without any complication (Figure 4A-C).

Lung abscess can be caused by dental infections, but simultaneous development of multiple abscesses in different organs is a rare condition. The general approach has been reviewed by the principles of diagnosis and therapy.

References

1. Mansharamani N, Balachandran D, Delaney D, Zibrak JD, Silvestri RC, et al. (2002) Lung abscess in adults: clinical comparison of immunocompromised to non-immunocompromised patients. *Respir Med* 96: 178-85.
2. Murdoch DR, Corey GR, Hoen B, Miro JM, Fowler VG, et al. (2009) Clinical presentation, etiology, and outcome of infective endocarditis in the 21st century: the International Collaboration on Endocarditis-Pro prospective Cohort Study. *Arch Intern Med* 169: 463-73.
3. Hirshberg B, Sklair-Levi M, Nir-Paz R, Ben-Sira L, Krivoruk V, et al. (1999) Factors Predicting Mortality of Patients With Lung Abscess. *Chest* 115: 746-50.
4. Johannsen EC, Madoff LC (2005) Infections of the liver and biliary system, In: Mandell GL, Bennett JE, Dolin R Mandell, Douglas and Bennett's Principles and Practice of Infectious Diseases. 6th ed Churchill Livingstone, Philadelphia 951-958.
5. <http://www.sciencedirect.com/science/article/pii/S1726490108701461>
6. Takayanagi N, Kagiyama N, Ishiguro T, Tokunaga D, Sugita Y (2010) Etiology and outcome of community-acquired lung abscess. *Respiration* 80: 98-105.
7. Wong WM, Wong BCY, Hui CK (2002) Pyogenic liver abscess: retrospective analysis of 80 cases over a 10 year period. *J GastroenterolHepatol* 17: 1001-1007
8. Chan KS, Chen CM, Cheng KC, Hou CC, Lin HY, et al. (2005) Pyogenic liver abscess: a retrospective analysis of 107 patients during a 3 year period. *Jpn Infect Dis* 58: 366-8.
9. Rockey DC (2001) Hepatobiliary infections. *Curr Opin Gastroenterol* 17: 257-261.
10. Wang JL, Chen KY, Fang CT, Hsueh PR, Yang PC, et al. (2005) Changing Bacteriology of Adult Community-Acquired Lung Abscess in Taiwan: Klebsiella pneumoniae versus Anaerobes. *CID* 40: 915-921.
11. Bartlett JG, Gorbach SL, Tally FP, Finegold SM (1974) Bacteriology and treatment of primary lung abscess. *Am Rev Respir Dis* 109: 510-518.
12. Mwandumba HC, Beeching NJ (2000) Pyogenic lung infections: factors for predicting clinical outcome of lung abscess and thoracic empyema. *Curr Opin Pulm Med* 6: 234-239.
13. Mohsen AH, Green ST, Read RC, McKendrick MW (2002) Liver abscess in adults: ten years experience in a UK centre. *QJM* 95: 797-802.
14. Ozol D, Oktem S, Erdinc (2006) Complicated parapneumonic effusion and empyema thoracis: microbiologic and therapeutic aspects. *Respir Med* 100: 286-291.
15. Appelbaum PC, Spangler SK, Jacobs MR (1990) B-Lactamase Production and Susceptibilities to Amoxicillin, Amoxicillin-Clavulanate, Ticarcillin, Ticarcillin-Clavulanate, Cefoxitin, Imipenem, and Metronidazole of 320 Non-Bacteroides fragilis Bacteroides Isolates and 129 Fusobacteria from 28 U.S. Centers. *Antimicrobial Agents And Chemotherapy* 1546-50.
16. Chung YFA, Tan YM, Lui HF (2007) Management of pyogenic liver abscesses-percutaneous or open drainage? *Singapore Med J* 48: 1158-1164.
17. Wang JL, Chen KY, Fang CT, Hsueh PR, Yang PC, et al. (2005) Changing Bacteriology of Adult Community-Acquired Lung Abscess in Taiwan: Klebsiella pneumoniae versus Anaerobes. *CID* 40: 915-921.

This article was originally published in a special issue, **Cardiology-Case Reports** handled by Editor(s). Dr. Arnon Blum, University of Miami, USA.