

## Post-Traumatic Peritoneopericardial Diaphragmatic Hernia: A Case Report

Katarzyna Szwalbe\*, Piotr Misiak and Artur Terlecki

Department of Thoracic Surgery, General and Oncological Surgery, University Clinical Hospital No.2, Military Memorial Medical Academy, Central Veterans' Hospital, Medical University of Łódź, Poland

\*Corresponding author: Katarzyna Szwalbe, Department of Thoracic Surgery, General and Oncological Surgery, University Clinical Hospital No.2, Military Memorial Medical Academy, Central Veterans' Hospital, Medical University of Łódź, Poland, Tel: +48422725803; E-mail: szwalbe@wp.pl

Rec date: Feb 10, 2017; Acc date: Mar 09, 2017; Pub date: Mar 11, 2017

Copyright: © 2017 Szwalbe K, et al. This is an open-access article distributed under the terms of the creative commons attribution license, which permits unrestricted use, distribution, and reproduction in any medium, provided the original author and source are credited.

### Abstract

The most common cause of traumatic diaphragmatic rupture is blunt or penetrating thoraco-abdominal trauma. The proper diagnosis can be difficult to make due to the non-specific clinical picture. The surgical approach in managing diaphragmatic rupture includes laparotomy, thoracotomy, or both. This article presents a case of a 60-year-old woman with post-traumatic peritoneopericardial diaphragmatic hernia. The study suggests that diaphragmatic injury should be considered in patients with blunt or penetrating thoraco-abdominal trauma.

**Keywords:** Antithrombotic drug; Intracranial hemorrhage; Therapy; Central nervous system; Anticoagulants

### Introduction

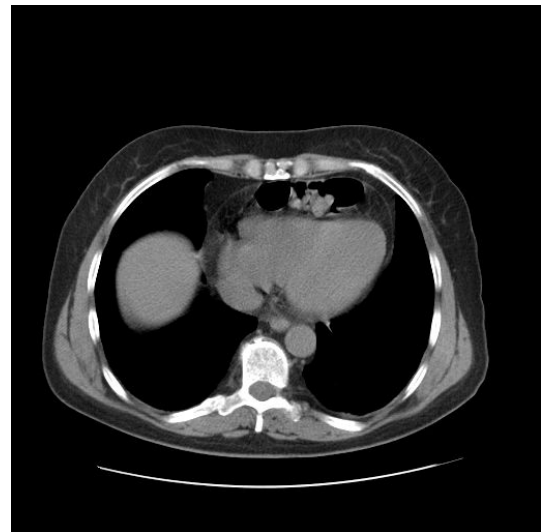Traumatic diaphragmatic rupture can result from blunt or penetrating thoraco-abdominal trauma. The most common causes are automobile accidents or falls from a height; such trauma is rarely caused by stabbing or gunshot wounds. A traumatic rupture of the diaphragm, with herniation of the abdominal viscera into the thoracic cavity, is relatively rare, being observed in 3% to 7% of all abdominal or thoracic traumas [1]. The diagnosis can be difficult because of associated injuries that are serious in nature, resulting in their proper diagnosis being a persistent problem in trauma centers. In this case report a rare type of diaphragmatic rupture, pericardio diaphragmatic rupture, is described that presented with recurrent abdominal pain. For patients with a history of trauma, complaining of non-specific epigastric pain, a delayed diaphragmatic hernia should always be considered.

### Case Report

A 60-year-old woman was admitted to the Department in June, 2008, following an automobile accident. She was diagnosed with cerebral concussion, left clavicular fracture and fracture of the 4th left rib. The patient made a complete recovery following treatment of these injuries. Despite several hospitalizations between 2008 and 2012 for recurrent abdominal pain, the correct diagnosis was not made until her hospitalization in November, 2012. During this hospitalization, chest X-rays revealed multiple gas shadows overlying the cardiac silhouette. Further investigation with computed tomography illustrated a trans-diaphragmatic bowel herniation into the anterior mediastinum (Figure 1).

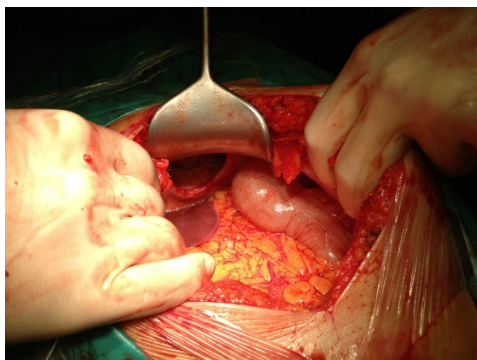
Based on this radiography, the patient was admitted to the Department of Thoracic Surgery, General and Oncological Surgery on 26 November 2012. On admission, the patient was in good overall condition. She complained of severe abdominal pain and bloating. She

was qualified for surgical intervention. A planned surgical procedure under general anesthesia was performed.



**Figure 1:** CT scan shows bowel in the pericardium.

The abdominal cavity was opened via a midline incision in the epigastrium. In the central portion of the diaphragm, a round defect measuring 5 cm across was observed. The transverse colon with its overlying omentum was determined to have herniated from the pericardial space, through the diaphragmatic defect, and into the mediastinum. The herniated bowel was manually reduced with ease (Figure 2) and the incision was closed with interrupted sutures. The postoperative period was uneventful with the patient being discharged on the second postoperative day.



**Figure 2:** Pericardio-diaphragmatic tear after removal of herniated bowel.

## Discussion

Traumatic diaphragmatic injury is relatively rare and has been reported in 0,8% to 1,6% of patients hospitalized due to blunt trauma [2]. The underlying mechanism of diaphragmatic rupture in blunt trauma is due to a sudden increase in intra-abdominal pressure, which may result in a linear tearing of the diaphragm. The normal positive gradient of 7 cm to 20 cm H<sub>2</sub>O can rise to as high as 100 cm H<sub>2</sub>O. In some cases, a small linear tear that occurs at the time of injury can suddenly enlarge due to this increase in the gradient in thoraco-abdominal pressure secondary to coughing or lifting of heavy weights [3]. Left-sided rupture occurs in 68.5% of patients, 24.2% of ruptures occur on the right side, 1.5% bilaterally, and 0.9% involve pericardial rupture [3,4].

The left diaphragm is more commonly involved, as its weakest point is located on the left posterolateral aspect of the pleuroperitoneal membrane. On the other hand, the right diaphragm is able to withstand greater intra-abdominal pressure gradients due to its being protected by the liver. The organs that most commonly herniate into the thorax include the stomach, spleen, colon, small bowel and liver.

Herniation of organs into the thoracic cavity imparts additional pressure on the lungs and causes the mediastinum to shift. This may lead to circulatory and respiratory disturbances. Grimes divided the clinical manifestation of the diaphragmatic rupture into three phases: The first is an acute phase at the time of injury to the diaphragm; the second is a delayed phase associated with transient herniation of the viscera, thus accounting for absent or intermittent non-specific symptoms; and the third is an obstruction phase involving complications associated with those of a long-standing herniation: obstruction, strangulation and posterior rupture [3].

The diagnosis in the acute phase can be difficult to make and is frequently overlooked because of serious related injuries and shock. Moreover, the diagnosis is delayed in up to 30% to 50% of cases; this delay can range from 7 days to 40 years [5]. Chest radiography is commonly the initial diagnostic test. The specific signs include intestinal air or a nasogastric tube above the hemidiaphragm, marked elevation of the hemidiaphragm, as well as mediastinal shift. The sensitivity of chest radiography has been reported to be as high as 70%. Computed tomography has a sensitivity of 75% to 90% and specificity approaching 100% [5,6].

The surgical approach includes laparotomy, thoracotomy or both, the decision being dependent upon the associated injuries and the condition of the patient at the time of admission. Laparotomy is more appropriate in unstable patients when associated intra-abdominal injuries are present or suspected. Thoracotomy is more suitable for stable patients without intra-abdominal injuries, contralateral diaphragmatic injuries or a delayed diagnosis [4,6].

## Conclusion

An accurate diagnosis of diaphragmatic rupture in trauma patients is difficult to carry out, resulting in decreased quality of life due to delayed treatment. Emergency physician and trauma surgeon should keep this diagnosis in mind in patients with a history of thoraco-abdominal trauma. In delayed cases, a thoracotomy is preferred because of the possible presence of adhesions. In this case the incision was closed with interrupted sutures but another problem with delayed treatment can be atrophy of the diaphragm, which may require reconstruction with prosthesis mesh. In conclusion, although the diaphragmatic hernias are rare and the clinical manifestation can be variable, they should always be considered in the trauma patient.

## References

1. Fleyfel M, Ferreira JF, Gonzalez De Linares H, Merlier O, Harchaoui A (1994) Cardiac tamponade after intrapericardial diaphragmatic hernia. *Br J Anaesthesiol* 73: 249-251.
2. Epstein LI, Lempke RE (1968) Rupture of right hemidiaphragm due to blunt trauma. *J Trauma* 8: 19-28.
3. Shah R, Sabanathan S, Mearns AJ, Choudhury AK (1995) Traumatic rupture of diaphragm. *Ann Thorac Surg* 60: 1444-1449.
4. Jablonski S, Santorek-Strumillo E, Wcislo Sz, Wawrzycki M, Misiak P, et al. (2009) Traumatic rupture of the diaphragm from the liver into the right pleural cavity-A case. *Half Merk Bow* 155: 478-482.
5. Regner JL, Leslie K, Raul C (2011) Acute presentation of chronic transdiaphragmatic intercostal hernia. *J Surg Radiol* 2: 259-268.
6. Tan KK, Yan ZY, Vijayan A, Chiu MT (2009) Management of diaphragmatic rupture from blunt trauma. *Singapore Med J* 50: 1150-1153.