

# Primary Lymphoma of Liver Showing Non-Hodgkin's B Cell Lymphoma. A Case Report

Akshay Nigam<sup>1</sup>, Anupama Sharma<sup>2\*</sup>, Ajay Kumar Singh<sup>2</sup>, Sanjeev Kumar Singh<sup>2</sup> and Girish Chandra Sharma<sup>3</sup>

<sup>1</sup>Department of Radiation Oncology, G. R. Medical College, Gwalior [M.P.] 474001, India

<sup>2</sup>Department of Biochemistry, G. R. Medical College, Gwalior [M.P.] 474001, India

<sup>3</sup>Division of Bioinorganic Chemistry, Department of Chemistry, Aligarh Muslim University [U.P.], India

## Abstract

Lymphoma, a common malignancy of liver called as primary lymphoma of liver or primary hepatic lymphoma (PHL). It's an unusual form of non-Hodgkin's lymphoma having symptoms such as hepatomegaly and signs of cholestatic jaundice. With appropriate treatment this hepatic lymphoma have relatively good prognosis. We report a case of 40 years old male with abdominal lump in epigastric region, having constant weight loss from one month and past fever history. Blood estimation leucocytosis were found with mild elevation in hepatic enzymes, on (fine needle aspiration cytology) FNAC lesions were seen in liver. Immunohistochemical examination showed high grade non-Hodgkin's B cell lymphoma. The radiographic and sonographic examinations were done. On diagnosis secondary metabolites of liver, systemic lymphoma with secondary involvement of liver and hepato-cellular carcinoma were seen. The patient responded for the chemotherapy and is still on follow-up.

**Keywords:** Primary hepatic lymphoma; Hepatic lymphoma; Non-Hodgkin's hepatic lymphoma; Radiotherapy; Hepato cellular carcinoma

## Introduction

A primary hepatic lymphoma (PHL) is defined as lymphoma localized and limited in the liver [1], not the secondary involvement of high or intermediate grade non-Hodgkin's lymphoma and accounts for less than 1% of all extra nodal lymphomas [2]. It's an unusual form of non-Hodgkin's lymphoma that usually present with constitutional symptoms, hepatomegaly and signs of cholestatic jaundice without lymph node and extra-hepatic (i.e., the spleen, bone marrow and other lymphoid tissue) lymphoma proliferation at early stage of the disease [1]. The prevalence of PHL is 0.4% among extra-nodal non-Hodgkin's lymphoma and 0.016% among all non-Hodgkin's lymphoma [2]. Because of its rarity, non-specific clinical symptoms, laboratory and imaging performance, PHL was often misdiagnosed as hepatitis, primary liver cancer or metastatic tumor. In this case report, we present a patient with pathologically confirmed primary hepatic diffuse large B cell lymphoma.

Among them, a primary hepatic low-grade marginal zone B cell lymphoma of mucosa-associated lymphoid tissue (MALT lymphoma) is extremely rare. On the other hand, hepatic pseudo-lymphoma (HPL), also termed as reactive lymphoid hyperplasia, or nodular lymphoid lesion is extremely rare disease and characterized by proliferation of non-neoplastic, polyclonal lymphocytes forming follicles with an active germinal center [3].

## Case Report

40 years old male presented to the Department of Radiotherapy, J.A. Group of Hospitals, Gwalior, India, with complaint of abdominal lump in epigastric region from 2 months (Figure 1A), with constant weight loss from one month, fever for 15 days of duration followed by night sweating. His medical history was unremarkable. On examination patient was conscious, oriented and afebrile. On abdomen examination there was a mass seen in epigastric region of abdomen which was firm in consistency and moves with respiration. Blood profile shows

decreased haemoglobin and leucocytosis. FNAC (fine needle aspiration cytology) of liver lesion showed it was a high grade malignant non-Hodgkin's B cell lymphoma. Immunohistochemistry showed high grade non-Hodgkin's B cell lymphoma.

The patient was further recommended for abdominal ultrasound. Large lobulated hypoechoic lesion was seen in lobe of liver (Figure 1B). Small lesion of same echogenicity was seen in right lobe of liver with minimal ascities (Figure 1C). No ultrasonographic evidence of intra abdominal lymphadenopathy was seen.

CECT (Contrast Enhanced Computed Tomography) of the abdomen showed hypo-attenuating lesion on non contrast and mildly enhancing lesion on contrast enhance image in right (Figure 1D) and left lobe of liver were seen with mild ascites (Figure 1E). The chest X-ray was normal.

After confirming the diagnosis of therapy plan include following doses of CHOP, (injection Cyclophosphamide 500 mg/m<sup>2</sup>, injection Vincristine 1.5 mg/m<sup>2</sup>, injection Doxorubicine 50 mg/m<sup>2</sup> and Tablet Wysolon 100 mg/m<sup>2</sup> in to 5 days). Six cycles were provided of following chemotherapy. There was almost 100 % response to the chemotherapy and patient is still on follow-up.

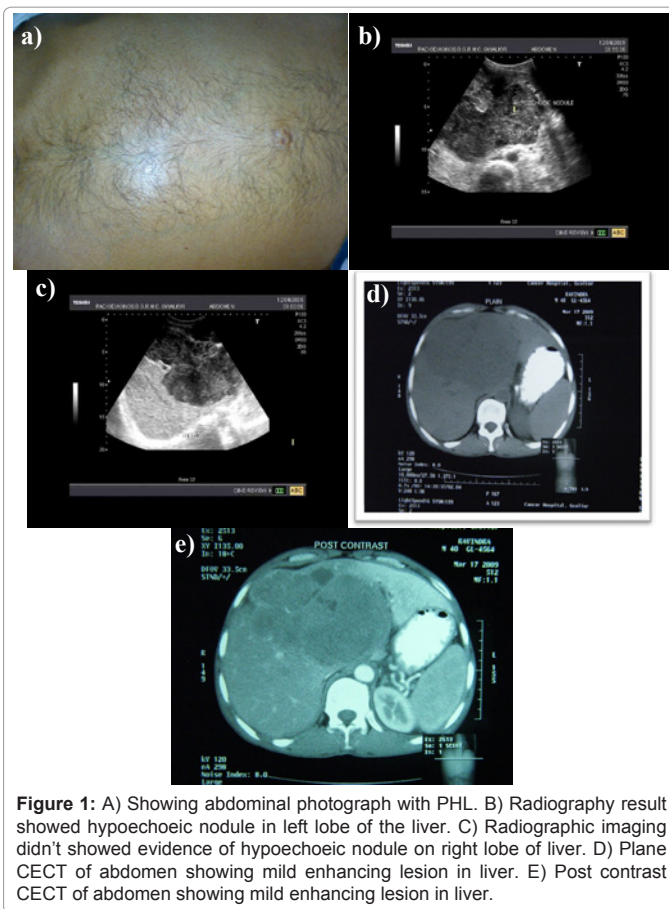
Sonography results shown nodular type as well as marginated solitary hypoechoic lobulated lesion seen in 60% cases, which is similar to nodular lymphoma elsewhere in the body. Multifocal lesion seen in 30% of cases and is commonly associated with immunodeficiency state,

\*Corresponding author: Anupama Sharma, Department of Biochemistry, G. R. Medical College, Gwalior [M.P.] 474001, India, E-mail: [shuananupama@gmail.com](mailto:shuananupama@gmail.com)

Received October 28, 2011; Accepted January 22, 2012; Published January 24, 2012

Citation: Akshay N, Anupama S, Ajay Kumar S, Sanjeev Kumar S, Girish Chandra S (2012) Primary Lymphoma of Liver Showing Non-Hodgkin's B Cell Lymphoma. A Case Report. J Cancer Sci Ther 4: 010-011. doi:10.4172/1948-5956.1000103

Copyright: © 2012 Akshay N, et al. This is an open-access article distributed under the terms of the Creative Commons Attribution License, which permits unrestricted use, distribution, and reproduction in any medium, provided the original author and source are credited.



**Figure 1:** A) Showing abdominal photograph with PHL. B) Radiography result showed hypoechoic nodule in left lobe of the liver. C) Radiographic imaging didn't showed evidence of hypoechoic nodule on right lobe of liver. D) Plane CECT of abdomen showing mild enhancing lesion in liver. E) Post contrast CECT of abdomen showing mild enhancing lesion in liver.

where as diffusion type of involvement was very rare. CT scan showed mildly enhancing hypo attenuating lesions in liver. MRI showed homogenous hyper intense signal on  $T_2$  weighted images and hyper intense signal of  $T_1$  weighted images.

## Discussion

Non-Hodgkin's lymphoma is a common malignant disease. Liver involvement occurs in 10% of patients, it is a sign of advanced disease of only 21% of all reported malignant liver cases. Disposing factors include immunosuppressive states like HIV. PHL refers to an extra-nodal lymphoma of the liver without involvement of any other organ (e.g, lymph node, spleen, etc) [3,4]. The vast majority (67%) of PHL patients are middle-aged men who usually present with abdominal pain, nausea and constitutional symptoms [4]. The male / female ration is 3:1 world wide. PHL is notably rare, representing <1% of all extra-nodal lymphoma [4].

Hepatitis B is not a risk factor for hepatic liver disease. Non-Hodgkin's lymphoma is more common in right hepatic lobe then in left lobe, clinically presented with the symptoms of right upper abdominal mass, epigastric pain and weight loss. If associated with symptoms of Hepatitis B, it indicates poor prognosis. In tumor no elevation seen in CEA (carcinoma embryonic antigen), AFP (alpha feto protein). Limited experience showed that PHL had non-specific clinical manifestations. Hepatomegaly is found in most patients with constitutional symptoms (e.g., fever, night sweats and weight loss) appear in 37%, fever in 86%, weight loss in 57% and jaundice in 4% [4-7]. Our patient showed all

the symptoms of Primary hepatic lymphoma of liver. In liver, PHL may present as a solitary mass (42%) or as multiple lesions (50%). Patients with PHL have abnormal liver function tests (cholestasis and cytotoxicity) [8,9] mostly elevated LDH and alkaline phosphatase (ALP) [7,10]. The cause of PHL is not entirely clear, but may be related to viral hepatitis [11]. Hepatitis C virus (HCV) infection is found in 20%–60% of patients with PHL. The frequent association with HCV suggests that this virus may play a role in the pathogenesis of PHL [8,9]. PHL is also seen in immunocompromised patients, but the relationship between PHL occurrence and immune deficiency has not yet been reported. Our patient had neither hepatitis C infection nor signs of immunodeficiency. Therefore, we speculated that PHL also could occur in patients without any prior liver disease. Diagnosis of PHL requires a liver biopsy compatible with lymphoma and absence of lymphoproliferative disease outside the liver.

In addition to physical examination, X-ray of the chest, skull and pelvis is a reliable method for detecting visceral and nodal dissemination and should always be performed.

On differential diagnosis secondary metabolites of liver, systemic lymphoma with secondary involvement of liver and hepato-cellular carcinoma were seen. At the time of diagnosis true cut biopsy was not possible, because the patient was bleeding too much. Leucocytopenia and WBC count and other finding are normal. LDH is not done but Liver function test were drenched. Patient was very poor so IHC, H and E were not done. The pathological pictures were lost by the patient.

Although it is an aggressive disease, it is resectable and responsive to chemotherapy and radiotherapy. After six cycles of chemotherapy 95% response was seen. Because of the profound therapeutics, it should be considered in differential diagnosis of secondary liver cancer.

## References

- Caccamo D, Pervez NK, Marchevsky A (1986) Primary lymphoma of the liver in the acquired immunodeficiency syndrome. Arch Pathol Lab Med 110: 553-555.
- Freeman C, Berg JW, Cutler SJ (1972) Occurrence and prognosis of extranodal lymphomas. Cancer 29: 252-260.
- Ishida M, Nakahara T, Mochizuki Y, Tsujikawa T, Andoh A, et al. (2010) Hepatic reactive lymphoid hyperplasia in a patient with primary biliary cirrhosis. World J Hepatol 2: 387-391.
- Lei KI, Chow JH, Johnson PJ (1995) Aggressive primary hepatic lymphoma in Chinese patients. Presentation, pathologic features, and outcome. Cancer 76: 1336-1343.
- Lei KI (1998) Primary non-Hodgkin's lymphoma of the liver. Leuk Lymphoma 29: 293-299.
- Zheng W, Yong WB, Zhu J, Zhang YT, Wang XP, et al. (2004) Clinical analysis of liver non-Hodgkin's lymphoma. Ai Zheng 23: 1451-1454.
- Page RD, Romaguera JE, Osborne B, Medeiros LJ, Rodriguez J, et al. (2001) Primary hepatic lymphoma: favorable outcome after combination chemotherapy. Cancer 92: 2023-2019.
- De Renzo A, Perna F, Persico M, Notaro R, Mainolfi C, et al. (2008) Excellent prognosis and prevalence of HCV infection of primary hepatic and splenic non-Hodgkin's lymphoma. Eur J Haematol 81: 51-57.
- Bronowicki JP, Bineau C, Feugier P, Hermine O, Brousse N, et al. (2003) Primary lymphoma of the liver: clinical-pathological features and relationship with HCV infection in French patients. Hepatology 37: 781-787.
- Avlonitis VS, Linos D (1999) Primary hepatic lymphoma: a review. Eur J Surg 165: 725-729.
- Matano S, Nakamura S, Annen Y, Hattori N, Kiyohara K, et al. (1998) Primary hepatic lymphoma in a patient with chronic hepatitis B. Am J Gastroenterol 93: 2301-2302.