

# Robotics in the MIS Spine Surgery Arena: A New Role to Advance the Adoption of Endoscopic Surgery as the Least Invasive Spine Surgery Procedure

Anthony T. Yeung\*

Desert Institute for Spine Care, USA

\*Corresponding author: Yeung AT, Desert Institute for Spine Care, USA, Tel: +1 602-944-2900; E-mail: ayeung@sciatica.com

Rec Date: Apr 26, 2017; Acc Date: May 08, 2017; Pub Date: May 13, 2017

Copyright: © 2014 Yeung AT. This is an open-access article distributed under the terms of the Creative Commons Attribution License, which permits unrestricted use, distribution, and reproduction in any medium, provided the original author and source are credited.

## Abstract

The role of robotics is gaining prominence as the technology of the future. In traditional spine surgery, accuracy of hardware placement, selection of ideal size and length of implanted screws and hardware for segmental fixation is desired and important even for experienced surgeons. Hardware placement in tight spaces is especially critical in the cervical and thoracic spine. Robotics will enhance patient safety as well as surgical results, for the protection of patients. By reducing surgical radiation exposure, it also protects patients as well as the surgeon and OR personnel. In endoscopic surgery, improving the accuracy of endoscopic trajectories with image guidance will also bring this aspect of MIS surgery to the surgical mainstream. Robotic techniques are evolving rapidly. Even in their current State of the Art, robotics offer significant advantages to the outpatient spinal surgeon by precise reproducible placement of hardware and endoscopes for minimally invasive approaches.

**Keywords:** Spine surgery; Endoscopic surgery; Robotics

## Introduction

The role of robotics is gaining prominence as the technology of the future. As surgical fusion procedures in spine become more complex and minimally invasive options continue to expand, robotics is touted as the way to help average surgeons become consistently good, or good surgeons becoming better, greatly reducing complications and improving results. In traditional spine surgery, accuracy of hardware placement, selection of ideal size and length of implanted screws and hardware for segmental fixation is desired and important even for experienced surgeons [1]. Hardware placement in tight spaces is especially critical in the cervical and thoracic spine. Robotics will enhance patient safety as well as surgical results, for the protection of patients. By reducing surgical radiation exposure, it also protects patients as well as the surgeon and OR personnel.

In endoscopic surgery, improving the accuracy of endoscopic trajectories with image guidance will also bring this aspect of MIS surgery to the surgical mainstream. There is already extensive experience by surgeons, especially in Asia. Finding the perfect trajectory will help the surgeon target the patho-anatomy of pain in endoscopic surgery. Available imaging from traditional x-rays, MRI's, CT scans, and 3D reconstruction all help the computer and robot to provide the perfect trajectory needed for endoscopic surgery through mobile tubular retractors. Once the endoscope is directed to the disc, epidural space and the foramen, visualized surgical decompression is facilitated for accurate targeting of the painful patho-anatomy [2]. Anatomic deformities from an aging process can be decompressed and corrected at the same time, using the least invasive tissue sparing techniques that avoid injury to normal anatomy.

In endoscopic surgery, it is well recognized that Intra-operative and immediate post-operative imaging is helpful in MIS spine surgery to confirm that the decompression is accomplished. For fusion and

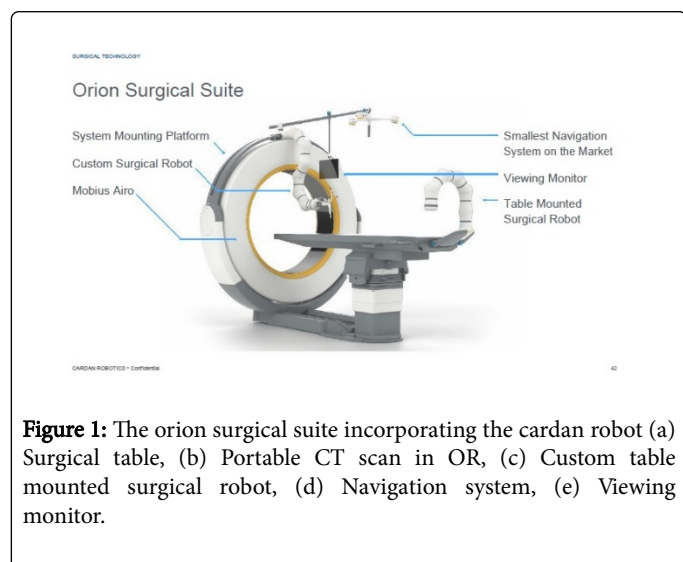
implant placement, especially for percutaneous screw placement and guidance for implants, there is no question that accuracy is desired. Radiation Safety is enhanced due to the adoption of image guidance and less dependence on fluoroscopy. The development of robotics to better standardize cannula and endoscope placement for Endoscopic Percutaneous Surgery will also have great impact on the development and standardization of the least invasive surgical decompression technique that will decrease the need for fusion by 75%, especially if applied early in the "disease" process.

Yeung's inside-out philosophy and Technique with Endoscopic trajectories incorporating his Artificial Intelligence is programmed into a Robot named Orion by Cardan Robotics. It will facilitate cannula placement for the various target points used in transforaminal endoscopic decompression [3]. A comprehensive compilation of trajectories for the majority of painful degenerative conditions of the lumbar spine is programmed in the Robot. This is guided by lessons learned from Anthony Yeung's 25 years' experience applying transforaminal endoscopic treatment of painful degenerative conditions of the Lumbar spine. Transforaminal Endoscopic Decompression, whether "inside out", "outside in" or targeted is featured. The concept of Foraminoplasty is differentiated from foraminotomy by Yeung as decompression of the hidden zone of MacNab between the traversing and exiting nerve. The more familiar posterior decompression approach can also be utilized and being developed by other endoscopic minimalists.

## Industry Developments Helping Endoscopic Procedures

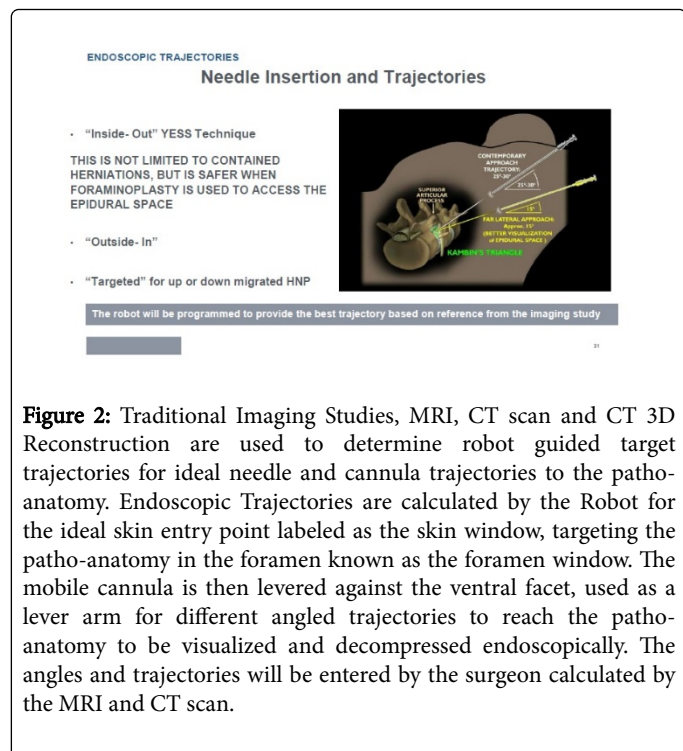
Multiple systems are currently available, but a surgical suite, incorporating Intra-operative CT scans from a rapid portable CT scanner (O-arm, Airo), aided by a Robotic Arm providing image guidance through Navigation will help facilitate endoscopic development, improve accuracy of instrument placement, insertion of

implants, and improve safety and results even for very experienced surgeons. It will shorten the learning curve for novice and less experienced surgeons as well. In endoscopic transforaminal surgery, it will shorten the long learning curve for surgeons who will be able to use it to recognize endoscopic normal and patho-anatomy. It can help with needle placement for diagnostic and therapeutic injections that when effective, will translate to successful endoscopic decompression. The Orion Surgical suite brings all the components together (Figure 1).

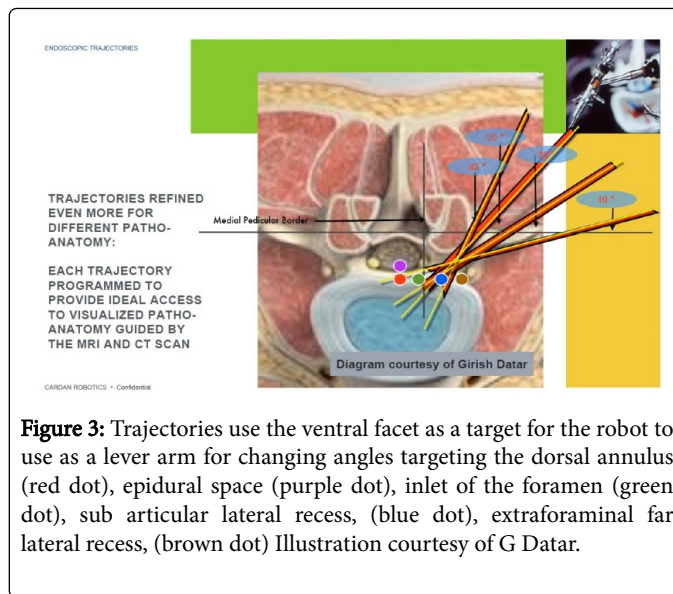


**Figure 1:** The orion surgical suite incorporating the cardan robot (a) Surgical table, (b) Portable CT scan in OR, (c) Custom table mounted surgical robot, (d) Navigation system, (e) Viewing monitor.

Moreover, the Robot mounted separately and can be used with other existing portable CT scanners such as the O-Arm, and other image guidance systems (Figures 2 and 3).

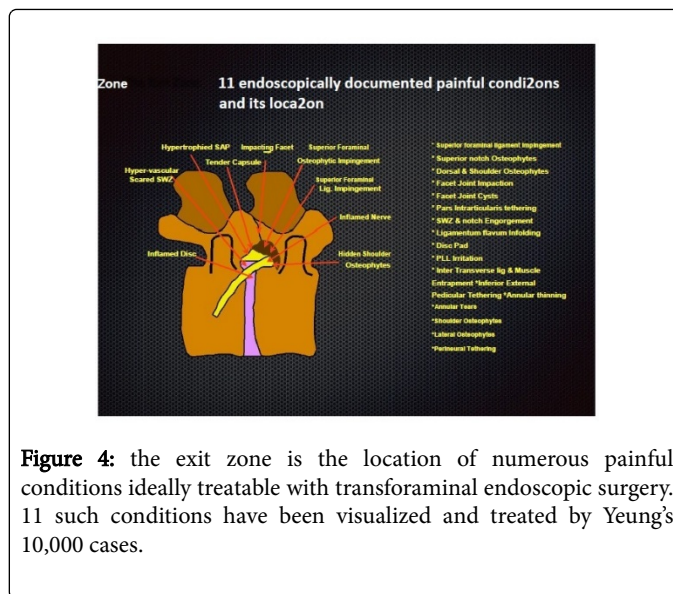


**Figure 2:** Traditional Imaging Studies, MRI, CT scan and CT 3D Reconstruction are used to determine robot guided target trajectories for ideal needle and cannula trajectories to the patho-anatomy. Endoscopic Trajectories are calculated by the Robot for the ideal skin entry point labeled as the skin window, targeting the patho-anatomy in the foramen known as the foramen window. The mobile cannula is then levered against the ventral facet, used as a lever arm for different angled trajectories to reach the patho-anatomy to be visualized and decompressed endoscopically. The angles and trajectories will be entered by the surgeon calculated by the MRI and CT scan.

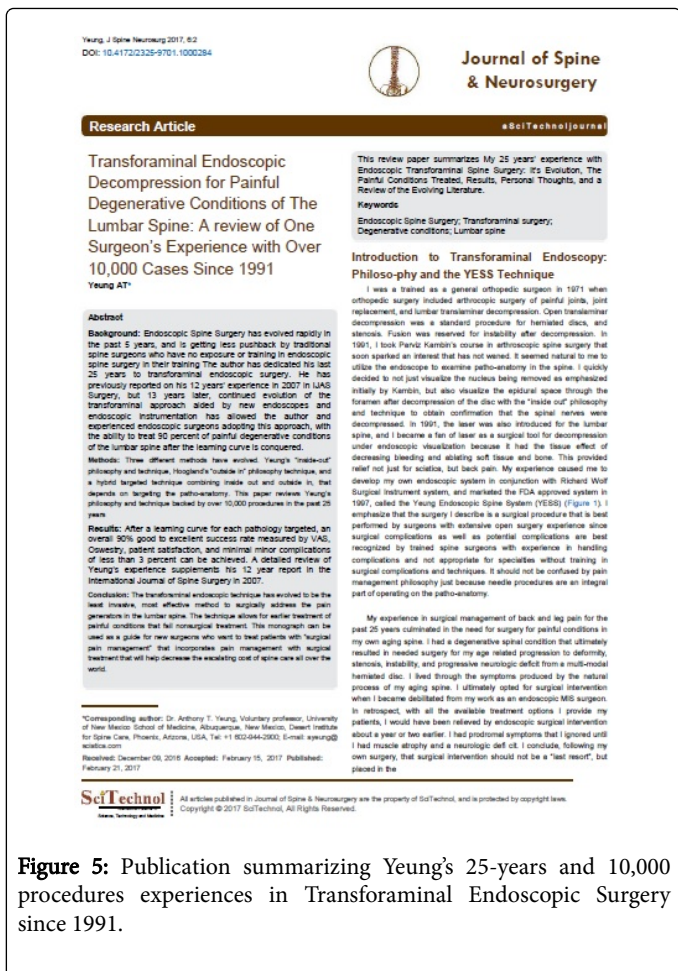

**Figure 3:** Trajectories use the ventral facet as a target for the robot to use as a lever arm for changing angles targeting the dorsal annulus (red dot), epidural space (purple dot), inlet of the foramen (green dot), sub articular lateral recess, (blue dot), extraforaminal far lateral recess, (brown dot) Illustration courtesy of G Datar.

The Orion system is the first to incorporate robotics for transforaminal endoscopic decompression. It is still in development expected to get US FDA approval in 2017 or 2018 (Figures 4 and 5).



**Figure 4:** the exit zone is the location of numerous painful conditions ideally treatable with transforaminal endoscopic surgery. 11 such conditions have been visualized and treated by Yeung's 10,000 cases.

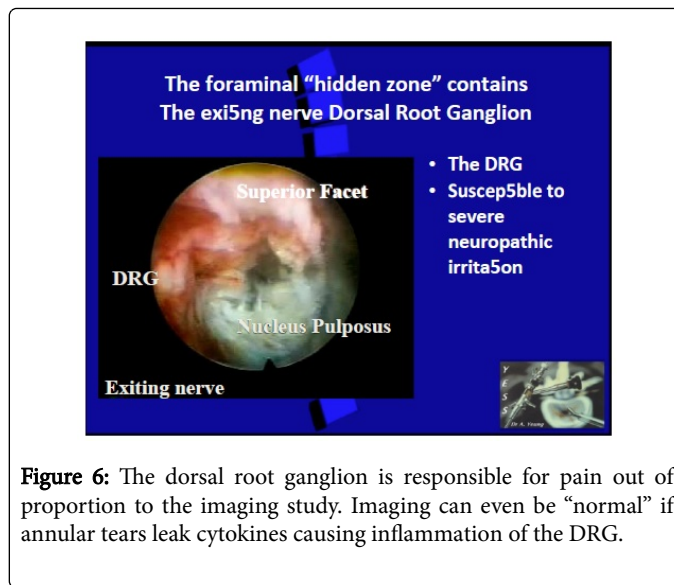


**Figure 5:** Publication summarizing Yeung’s 25-years and 10,000 procedures experiences in Transforaminal Endoscopic Surgery since 1991.

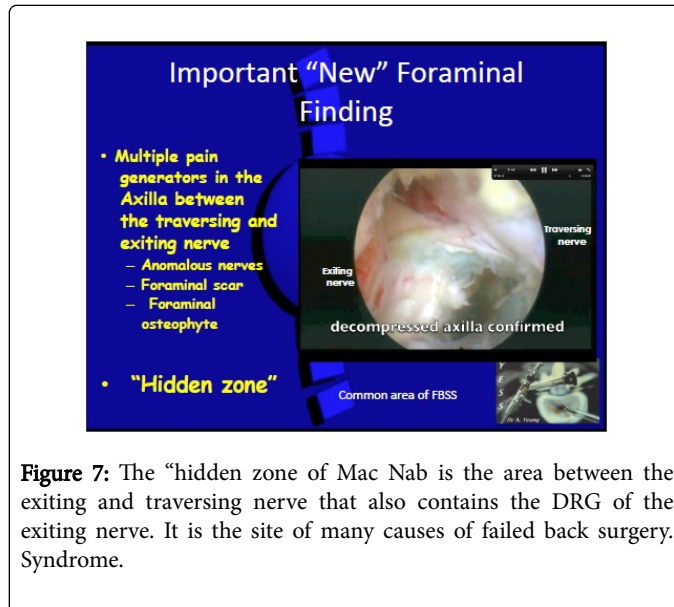
## Discussion

From A Yeung’s experience, the most common treatable conditions accomplished by treating the pain source are as follows:

1. Discogenic pain from toxic annular tears.
2. All types of HNP.
3. Stenosis (both central and foraminal).
4. “Stable” degenerative and isthmic spondylolisthesis.
5. Adjacent level HNP and degeneration.
6. Failed back surgery syndrome (Figures 6 and 7).
7. Neuropathic pain.

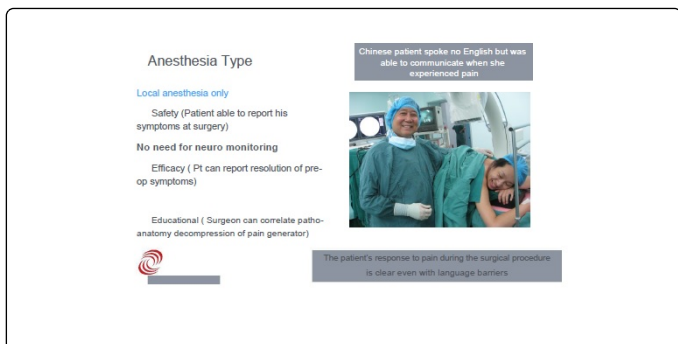


**Figure 6:** The dorsal root ganglion is responsible for pain out of proportion to the imaging study. Imaging can even be “normal” if annular tears leak cytokines causing inflammation of the DRG.



**Figure 7:** The “hidden zone of Mac Nab is the area between the exiting and traversing nerve that also contains the DRG of the exiting nerve. It is the site of many causes of failed back surgery Syndrome.

For the accomplished endoscopic surgeon, the need for fusion will be mitigated and decreased approximately 75% by stratifying patient selection, focusing on treating the painful patho-anatomy earlier rather than later in the painful disease process (Figure 8).




**Figure 8:** Operating under local anesthesia with or without sedation provides an extra layer of safety. If sedation is provided, only 4-5 cc fentanyl and versed is needed.

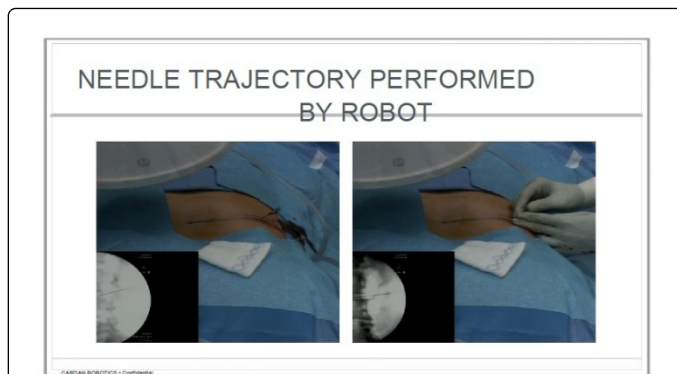
Endoscopic decompression can identify and treat the variations of normal patho anatomy inherent in patients either as a variation of normal anatomy or as a function of anatomic changes including instability from the aging process.

### Case examples of difficult transforaminal approaches that will be facilitated by robotic guidance of ideal trajectories

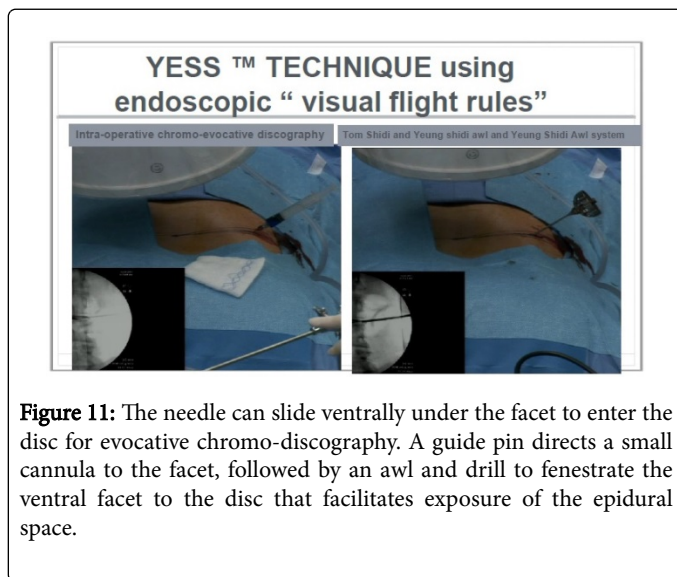
Examples of painful conditions in the lumbar spine that are amenable to transforaminal endoscopic decompression can be divided into basic and advanced techniques. The robot will facilitate endoscopic decompression for beginner as well as advanced endoscopic surgeons (Figures 9-11).



**Figure 9:** this extruded two sequestered fragment HNP requires special trajectories to target the two fragments. To directly target the most migrated fragment, a trajectory to the ventral facet will allow for outside –in foraminoplasty to directly target the more migrated fragment. The partially extruded fragment can then be removed with the “inside –out technique by entering the disc cavity to extract the other fragment whose base inside the disc cavity should also be removed. Other loose fragments will be removed to decrease the incidence of recurrence through the herniation defect. The more migrated fragment may be able to be removed without foraminotomy/foraminoplasty, but there is a chance that the sequestered migrated fragment could be missed if extraction is only from the disc cavity. The outside-in trajectory will assure a targeted approach.



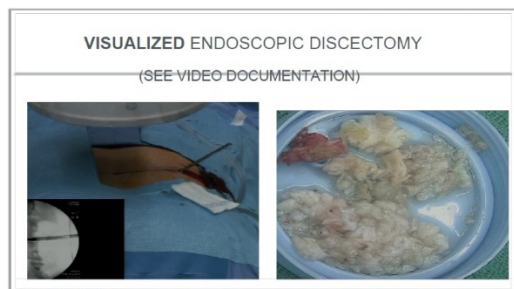**Figure 10:** the robot calculates for a 30-degree trajectory to the ventral facet. A targeted method facilitates removal of the patho-anatomy from the skin window to the foraminal window.



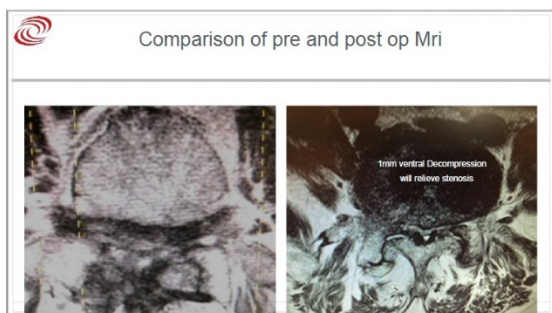**Figure 11:** The needle can slide ventrally under the facet to enter the disc for evocative chromo-discography. A guide pin directs a small cannula to the facet, followed by an awl and drill to fenestrate the ventral facet to the disc that facilitates exposure of the epidural space.

The basic techniques are for intradiscal therapies represented by the following:

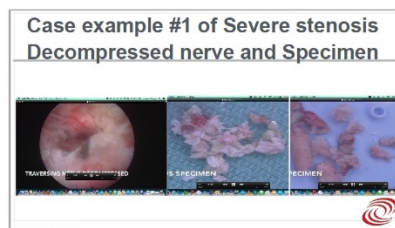
1. Toxic annular tears, (intradiscal therapy).
2. Discogenic and axial back pain, (selective endoscopic discectomy (Figures 12-14) and dorsal rhizotomy).
3. Multimodal HNP.
4. Failed back surgery syndrome.
5. Neuropathic pain using neuromodulation of the DRG. Advanced techniques are helped by using robotic guidance for ideal cannula trajectories (Figure 15).



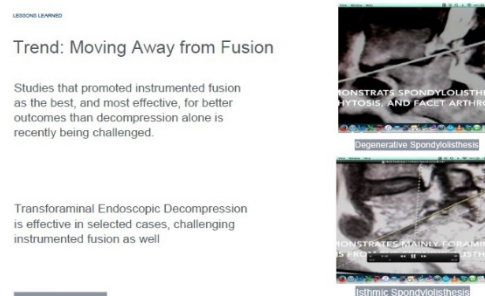**Figure 12:** The “medium tang” cannula of the YESS system is then inserted down a blunt 2 hole obturator that the YESS endoscope traverses to perform visualized discectomy. The red disc material represents the inflamed extruded herniation, and the light blue disc is degenerated nucleus removed from the disc cavity.



**Figure 13:** Extreme Case Example #1. An 82-yr-old male with severe foraminal and central spinal stenosis that translaminar decompression would be the choice of 100% of spine surgeons, including A Yeung. The patient elected, however, to undergo a transforaminal endoscopic decompression, when he was told that an open procedure would be an alternative option if his relief were not sufficient even though it would be easier for translaminar decompression. He is one year post- op and pleased with his choice and with his surgical result. Ventral decompression is very effective when technically feasible.



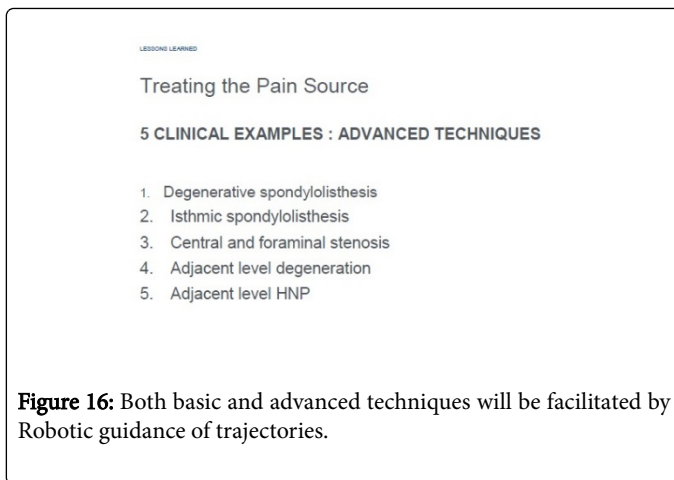
**Figure 14:** The decompressed traversing nerve was identified during surgery, and the patient, under local anesthesia was able to report discomfort when the annulus was being resected, but after decompression, pain relief was experienced intra- operatively and post-operative in the recovery room. The annulus was resected under the traversing nerve and visualized free of impingement. The ventral facet of the superior articular process was also removed to decompress to gain access to the epidural space, also relieving the patient’s symptoms foraminal stenosis causing weakness and intermittent claudication at the follow-up appointment one month later.



**Figure 15:** This patient with a stable grade II degenerative spondylolisthesis only had chronic sciatica from foraminal stenosis. Foraminoplasty resolved the patient’s sciatic pain and numbness. The payer push back for expensive fusion can be reduced 75% in a stratification of indications that focuses on the patho-anatomy and patho-physiology rather than just on the imaging. The disc is already collapsed, but symptoms are from nerve impingement rather than from instability.

### Surgeons and Robotics

The surgeon’s level of experience is the most important factor in transforaminal endoscopic surgery (Figure 16).



Robotics will significantly shorten the learning curve by improving accuracy, and provide patients who want to stage their surgery and have a chance to eliminate fusion as an early surgical option.

## Conclusion

Robotic techniques are evolving rapidly. Even in their current State of the Art, robotics offer significant advantages to the outpatient spinal

surgeon by precise reproducible placement of hardware and endoscopes for minimally invasive approaches. For endoscopic surgical decompression, especially transforaminal endoscopic surgery, placement of cannulas and endoscopes, the diminished radiation, and eliminating trauma to normal anatomy from surgical approaches pro will revolutionize MIS spine surgery and allow for the least invasive, most effective surgical approach in spine care.

Case examples will demonstrate the technology and Yeung and other endoscopic KOLs A.I., using robotics. It will help improve results, enhance patient safety, and improve efficacy of outpatient as well as inpatient MIS surgery.

For featuring case examples etc. You tube videos of playlists at [www.sciatica.com](http://www.sciatica.com).

## References

1. Van Dijk JD, Van den Ende RP, Stramigioli S, Köchling M, Höss N (2015) Clinical pedicle screw accuracy and deviation from planning in robot-guided spine surgery. *Spine* 40: E986-E991.
2. Xiaobang H, Donna O, Isador L (2013) Robotic assisted pedicle screw placement: Lessons learned from the first 102 patients. *Eur Spine J* 22: 661-666.
3. Stürer C, Ringel F, Stoffel M, Reinke A, Behr M, et al. (2011) Robotic technology in spine surgery: Current applications and future developments. *Acta Neurochir Suppl* 109: 241-245.