

Successful Treatment of Vitiligo by Needling with Topical 5 Fluorouracil

Maya Vedamurthy*, Aarthi Moorthy and Soumya Samuel

RSV Skin and Laser Centre, Chennai, India

*Corresponding author: Maya Vedamurthy, RSV Skin and Laser Centre, Chennai, India, Tel: 04428172172; E-mail: rsvskin@yahoo.in

Received date: April 28, 2016; Accepted date: August 26, 2016; Published date: September 05, 2016

Copyright: © 2016 Vedamurthy M, et al. This is an open-access article distributed under the terms of the Creative Commons Attribution License, which permits unrestricted use, distribution, and reproduction in any medium, provided the original author and source are credited.

Abstract

Introduction: Vitiligo is a chronic acquired disorder presenting with depigmented macules and patches. The response to treatment is variable as no single therapy produces predictably good results. Needling with topical 5% 5 fluorouracil in vitiligo has been found to be promising, effective and safe modality of treatment.

Materials and methods: Three patients with stable vitiligo were on medical treatment and phototherapy for two to three years. All the patients were not satisfied in terms of repigmentation. They were subjected to needling with topical 5% 5 fluorouracil application every 2 weeks for three months, along with their ongoing therapy.

Results: All the patients showed >75% improvement in terms of repigmentation of the achromic patches.

Conclusion: This method of needling with application of 5 fluorouracil cream is simple, safe and cost effective method for treating patients with stable vitiligo.

Keywords: Vitiligo; Needling; 5% 5-Fluorouracil; Repigmentation

Introduction

Vitiligo is a chronic acquired disorder characterised by development of depigmented macules which slowly enlarges with concurrent appearance of new lesions [1]. It affects approximately 1-2% of the world population irrespective of the age and sex. It is of great cosmetic concern. In vitiligo there is total or partial loss of melanocytes. Medical treatment is the primary mode of therapy to achieve repigmentation [2].

But, in patients recalcitrant to medical treatment alone, various surgical therapies can be used either alone or in conjunction with medical treatment to achieve repigmentation provided the disease is stable. Needling followed by topical application of 5% 5 fluorouracil is a recent advancement to the treatment modality of vitiligo.

In the present case series, we report three cases of vitiligo who had no or minimal repigmentation of the achromic patches with conventional therapy, and responded to addition of needling with application of topical 5 fluorouracil treatment leading to significant repigmentation.

Case Report

Case 1

A 5 year old boy was suffering from vitiligo over the left side of the chin and lower lip for over three years. He was on minipulse oral steroids and targeted phototherapy regularly for two years. The parents were unsatisfied in terms of repigmentation of the achromic patches (as mentioned in Figure 1).

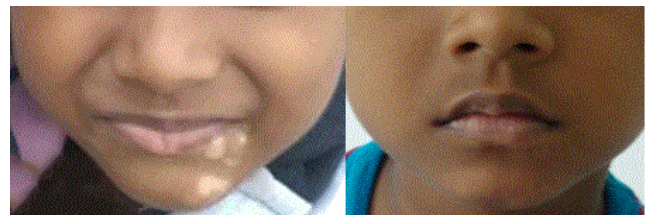


Figure 1: A: patient prior to therapy, B: the same patient after three months of needling with 5 Fluorouracil.

Case 2

A 28 year old male with vitiligo patches over the anterior aspect of right leg for last 10 years. He was treated with oral methylprednisolone pulse therapy, psoralen and phototherapy regularly for 3 years. Despite all this, he did not achieve significant repigmentation in terms of cosmetic coverage of the achromic patches (as mentioned in Figure 2).

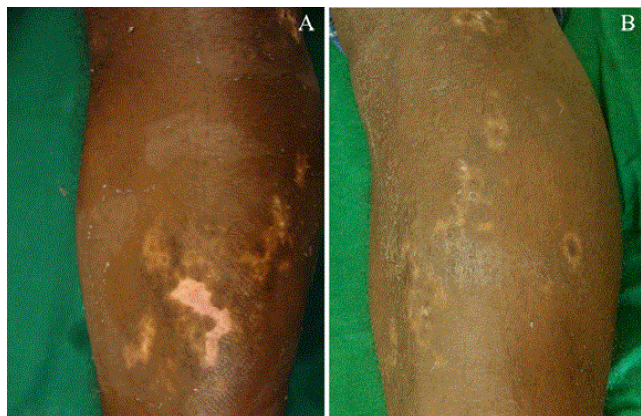


Figure 2: A: Patient prior to therapy, B: the same patient after three months of needling with 5 fluorouracil.

Case 3

A 22 year old girl with vitiligo patches over the dorsa of both feet was on conventional therapy with no significant improvement over the past two years (as mentioned in Figure 3).

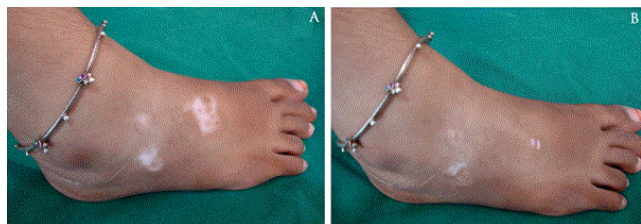


Figure 3: A patient prior to treatment B the same patient after three months of treatment with needling and 5 fluorouracil

Procedure

The affected area was surgically cleansed with Betadine followed by normal saline. A 26 gauge sterile hypodermic needle was used to make multiple superficial punctures over the achromic patches so as to cause minute pin point bleeding at the site of penetration and a thin layer of 5% 5 fluorouracil cream was applied.

Followed by which minimal crusting with scab formation was observed on 2nd or 3rd day. Each procedure required 5-10 min depending on the size of the patches to be treated. All the patients were advised to continue with their on-going medical treatment and phototherapy.

The procedure was repeated every two weeks.

Evaluation

Objective evaluation was made with pre and post treatment clinical photographs. Patients also assessed the percentage of repigmentation achieved on subjective assessment scale of 0-4 (0: no improvement; 1:

1-25% improvement; 2: 26-50% improvement; 3: 51-75% improvement; 4: 76-100% improvement).

Results

All patients reported subjective increase in pigmentation over the vitiligo patches after two sessions of the procedure which was confirmed with objective findings. At the end of three months, all three patients had more than 75% improvement and were highly satisfied with the treatment. It was also observed that the first case (5 years old boy) had the maximum improvement which could be a possibility that this mode of vitiligo management might have best outcome in younger individuals and it needs to be further evaluated.

Discussion

Vitiligo is an acquired condition that presents with achromic macules and patches [3,4]. Though this condition is not associated with systemic complications, it is of a great cosmetic concern, particularly in India where it causes psychological problems due to the stigma attached to it [5]. Many patients are refractory to medical treatment alone hence various surgical techniques and modifications have been used to treat stable recalcitrant vitiligo ever since 1964 [6]. Application of 5 fluorouracil after therapeutic wounding, as a treatment for vitiligo was introduced by Suji and Hamada in 1983 [7,8].

Its efficacy was successively confirmed by other authors [9-11]. Various techniques used to produce therapeutic wounding are dermabrasion, laser ablation, cryosurgery, local application of phenol, trichloroacetic acid and needling [9]. The simplest and effective technique among these is needling. A strong inflammatory reaction is seen after needling followed immediately by application of topical 5 fluorouracil. Due to this there is local oedema, which increases the intercellular spaces of the basal layer for a long time [12]. Active melanocytes with frequently vacuolated cytoplasm are found migrating from the pigmented to the achromic epidermis through these enlarged intercellular spaces [13].

Further the inflammatory mediators such as leukotrienes C4 and D4 are locally released, which would stimulate melanocyte proliferation and migration [13,14]. The metalloproteinase 2, synthesized by the keratinocytes during the epidermis remodelling process has been found to help in melanocyte migration [15]. These favourable milieu which persist for long time, could explain the successful migration of melanocytes from the pigmented area to the achromic area.

Conclusion

The efficacy of the conventional therapies with respect to repigmentation of vitiligo patches is unsatisfactory in many patients. The present case series shows that the addition of needling with 5 fluorouracil application augments the response even in poor responders to conventional therapy. The advantages of the procedure are that it is safe, simple, cost effective and can be done as an outpatient procedure.

References

1. Mosher DB, Fitzpatrick TB, Hori Y, Eisen AZ, Wolff k, et al. (1993) Disorders of melanocytes. *Dermatology in General Medicine* (4th edtn) Mc-Graw-Hill Inc 923-933.

2. Jimbow K (1998) Vitiligo: Therapeutic advances. *Dermatol Clin* 16: 399-407.
3. Grimes PE (1993) Vitiligo: An overview of therapeutic approach (review). *Dermatol Clin* 11:3254-3358.
4. Kovacs SO (1998) Vitiligo. *J Am Acad Dermatol* 38: 647-666.
5. Savant SS (2005) Surgical therapy of vitiligo: Current status. *Indian J Dermatol Venereol Leprol* 71: 307-310.
6. Westerhof W, Löntz W, Vanscheidt W, Braathen L (2001) Vitiligo: News in surgical treatment. *J Eur Acad Dermatol Venereol* 15: 510-511.
7. Tsuji T, Hamada T (1983) Topically administered fluorouracil in vitiligo. *Arch Dermatol* 119: 722-727.
8. Savant SS (1996) Therapeutic spot and regional dermabrasion in stable vitiligo. *Indian J Dermatol Venereol Leprol* 62: 139-145.
9. Szekeres E, Morvay M (1985) Repigmentation of vitiligo macules treated topically with Efudix cream. *Dermatologica* 171: 55-59.
10. Monk B (1985) Topical fluorouracil in vitiligo. *Arch Dermatol* 121: 25-26.
11. Sethi S, Mahayan BB, Gupta RR, Ohri A (2007) Comparative evaluation of the therapeutic efficacy of dermabrasion, dermabrasion combined with topical 5% 5-fluorouracil cream and dermabrasion combined with topical placentrex gel in localized stable vitiligo. *Int J Dermatol* 46: 875-879.
12. Waldorf DS, Engel ML, Van Scott EJ (1966). Inhibition of wound epithelialization by topical 5-fluorouracil. *Arch Dermatol* 94: 786-789.
13. Morelli JG, Kincannon J, Yohn JJ, Zekman T, Weston WL, et al. (1992) Leukotriene C4 and TGF-alpha are stimulators of human melanocyte migration in vitro. *J Invest Dermatol* 98: 290-295.
14. Morelli JG, Yohn JJ, Lyons MB, Murphy RC, Norris DA (1989) Leukotrienes C4 and D4 as potent mitogens for cultured human neonatal melanocytes. *J Invest Dermatol* 93: 719-722.
15. Lei TC, Vieira WD, Hearing VJ (2002). In vitro migration of melanoblasts requires matrix metalloproteinase-2: implications to vitiligo therapy by photochemotherapy. *Pigment Cell Res* 15: 426-432.