

# Surgical Procedure through Symbotex™ Medtronic Polyester with a Collagen Surface

Evangelos Kanavos

General Surgery Department, Iaso Thessalias, Greece

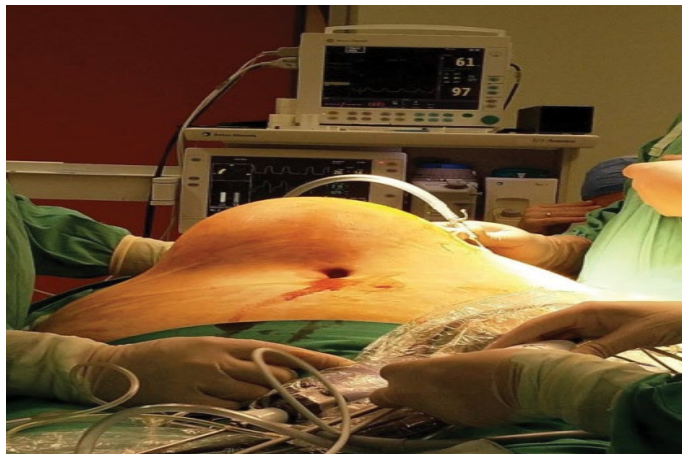

Figure 1. Big epigastric hernia before surgery.

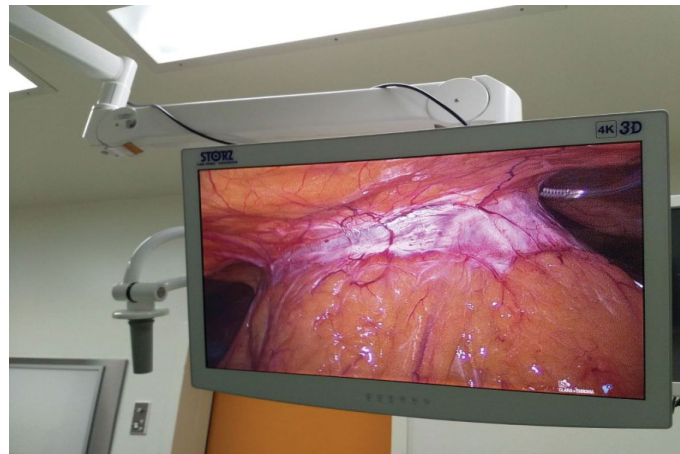


Figure 3. Laparoscopic image of epigastric hernia.

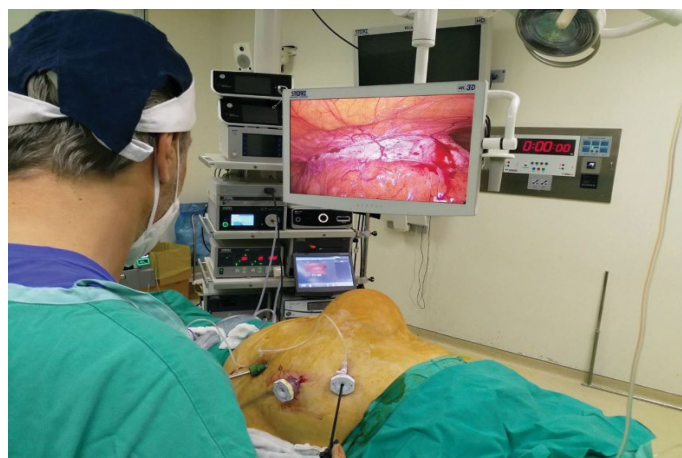

Figure 2. Robotic hernia repair. Port placement for robotic hernia repair distant from mesh placement area.

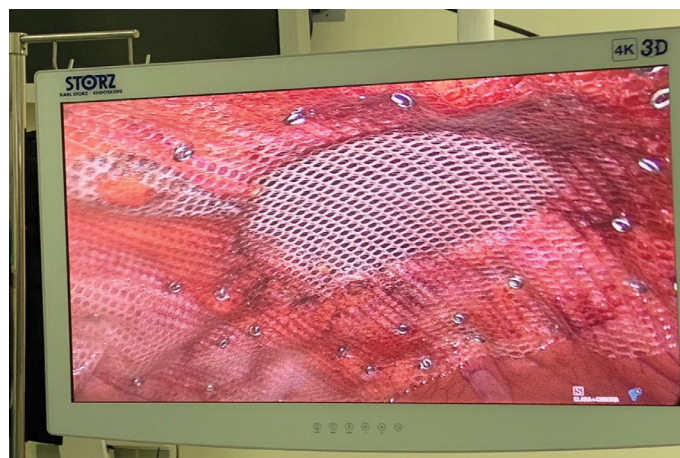


Figure 4. Closure of the defect and overlay mesh placement composed of Symbotex Medtronic polyester 25 × 20 cm.

## Clinical Images

A hernia is defined as protrusion of viscus through a defect in the containing cavity wall. Protrusion of the tissue in the linea Alba between the xiphoid process and umbilicus is called as epigastric hernia. Among all abdominal hernias epigastric hernias constitute 1.6% to 3.6%. Among operated hernias up to 5% are constituted by epigastric hernias. Epigastric hernias are more

**\*Address for Correspondence:** Evangelos Kanavos, General Surgery Department, Iaso Thessalias, Greece, Tel: +306978328168; E-mail: e-kanavos@hotmail.com

**Copyright:** © 2021 Kanavos E. This is an open-access article distributed under the terms of the Creative Commons Attribution License, which permits unrestricted use, distribution, and reproduction in any medium, provided the original author and source are credited.

Received 22 June 2021; Accepted 26 June 2021; Published 29 June 2021

commonly observed in middle-aged men between 20 to 50 years and among obese patients (Figure 1).

Epigastric hernias contain preperitoneal fat and are diagnosed using ultrasonography of the abdominal wall. Surgical treatment of epigastric hernia particularly of obstructed epigastric hernia is crucial as delay can result in strangulation, need for bowel resection resulting in prolonged recovery and increased risk of complication. Surgery offers permanent cure as there are chances of incarcerations are high. In case the content of gangrenous exploratory laparotomy with resection of gangrenous segment and anastomosis or ileostomy is the treatment of choice depending on patient condition (Figure 2).

Repositioning of the hernia sac contents and direct closure of the hernia opening required continuous suture. However, the repair needs to be augmented using mesh placement. Since the rate of recurrence of epigastric hernia is as high as 10 to 20%, tension free repair by placement of polypropylene mesh is preferable as this will restore the anatomy of the abdominal wall in a tension-free manner (Figure 3).

Current mesh fixation strategies is based on penetrating sutures and may result in complications such as pain, adhesions, erosions, or anchor migrations. Therefore, a bioadhesive self-fixation material system is preferable for abdominal wall repair in both open and laproscopic procedures. The choice of the mesh plays an important role in in the outcomes after ventral or incisional repair. It was observed that recurrence rates are lower when there is high mesh area to defect area ratio or atleast 5 cm of mesh overlap. However, there could be long term complications such as adhesion formation, and damage to adjacent vicera. This led to the development of intraperitoneal multifilament polyester onlay mesh providing a continuous protective layer. Later on surgeons sought to improve handling characteristics and memory

shape which led to development of monofilament polyester knitted structure called as Symbotex™ composite mesh.

Symbotex™ polyethylene terephthalate (polyester) textile composite mesh enables easy mesh deployment and placement in the abdominal cavity with excellent tissue integration, and minimal visceral attachment. The material has bioabsorbable film technology and impressive resistance to surgical handling and excellent abdominal wall clinging with few superficial surgical site infection. This mesh has pore size of  $2.1 \times 3.0$  mm and is made up of monofilament polyester mesh and with density of  $64 \text{ g/m}^2$ . On the visceral surface it has absorbable hydrophilic film consisting of a mixture of collagen and glycerol (Figure 4).

**How to cite this article:** Evangelos Kanavos. "Surgical Procedure through Symbotex™ Medtronic Polyester with a Collagen Surface". *J Cardiovasc Dis Diagn* 9 (2021) 9:456