

What does Doppler Ultrasonography Brings to the Diagnosis of Traumatic Vertebral Artery Dissection

Paola Caruso*, Paolo Manganotti and Rita Moretti

Department of Clinical Neurology, University of Trieste, Trieste, Italy

Abstract

Here we describe the case of a young woman with a late diagnosis of vertebral artery dissection and midbrain ischemic lesion after minor post traumatic injury. Doppler ultrasonography was used as the first diagnostic examination to evaluate the dissection. We present this unusual but not rare case related to the frequent events of cervical distraction after car accident in order to better understand the clinical approach the sensitivity Doppler ultrasonography in post-traumatic cervical distorsion.

Keywords: Vertebral artery dissection; Ultrasound examination; Hemodynamic signs

Introduction

Here we describe the case of a young woman with a late diagnosis of vertebral artery dissection and midbrain ischemic lesion after minor post traumatic injury. Doppler ultrasonography was used as the first diagnostic examination to evaluate the dissection. We present this unusual but not rare case related to the frequent events of cervical distraction after car accident in order to better understand the clinical approach the sensitivity Doppler ultrasonography in post-traumatic cervical distorsion. Vertebral-artery dissection (VAD) can be estimated at 1 per 100,000 to 1.5 per 100,000. Spontaneous dissections of the carotid or vertebral artery account for only about 2 percent of all ischemic strokes. Traumatic dissection occurs in approximately 1% of all patients with blunt injury mechanisms, and is frequently initially unrecognized. Conventional angiography or magnetic resonance angiography (MRA) are considered as the gold standard to diagnose VAD; CT angiography (CTA) and Doppler ultrasonography are described less frequently in literature, even if CTA is considered more sensitive (100%) than either MRA (77%) or Doppler ultrasonography (71%) in several studies. The peculiarity of this case is that minor cervical injury produced severe vertebral dissection and that Doppler ultrasonography is as sensitive and specific than CT angiography suggesting its possible use in routine diagnostic artery dissection's protocol.

Case Report

A 50-year-old Caucasian female, normally fit and well, presented to the emergency department because of a minor cervical trauma with extension injury to the neck due to a car accident. She presented two times to the emergency department for a sudden bursting headache with intermittent neck pain rotatory vertigo and neurovegetative symptoms (nausea). Only after 12-24 hours she complained also dysphonia. She was admitted in the Hospital. On neurological examination at the admission, level of consciousness, cognition speech, sensibility and strength were normal, the cranial nerve examination showed nystagmus type II towards the left, left ptosis, bilateral differences in the diameter of the two pupils, anisocoria, with the left bigger compared to the right ones. Pain was diffuse in the back of the neck without specific lateral localization and irradiated to the shoulders. Hematologic, biochemical and immunologic investigations were normal and electrocardiogram was unremarkable. Initial brain computed tomography (CT) showed high signal in the left vertebral artery, suggestive of thrombosis, but no evidence of low-signal change in the parenchyma. CT angiography (CTA) was performed demonstrating hyperdense left vertebral artery with irregularity of the lumen and a possible mural thrombus (thickened wall, often with some surrounding stranding) (Figure 1).

Patient was admitted to the stroke unit of our department and color-duplex ultrasound was performed. Examination showed, on B-mode imaging, thrombus detected as a thickened hypoechoic vessel wall, anyway wall hematoma and intraluminal thrombus cannot be differentiated with B-mode imaging, moreover, as not seen before, a double lumen with different signals was identified. Beside morphological finding hemodynamic signs could be detected, along the all vessel from the V1 segment of the VA to the V3 segment, color flow imaging showed areas of abnormal flow such as color aliasing, flow was irregular and demodulated with minor systolic picks (VPS 27 cm/s) and none diastolic picks could be identified (according to vessel distal obstruction finding), in V3 segment vessel was extremely windy (Figures 2 and 3).

Looking at the all examination the patient was started on anticoagulation therapy with heparin and bridged to warfarin as secondary prevention. During recovery patient complained

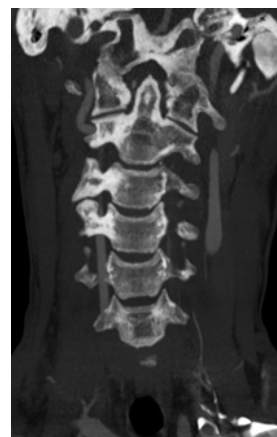

Figure 1: Angio TC imaging showing left vertebral artery with irregularity of the lumen and a possible mural thrombus.

*Corresponding author: Paola Caruso, Department of Clinical Neurology, University of Trieste, Trieste, Italy, Tel: +39 040 558 7111; E-mail: caruso.paola1983@libero.it

Received February 18, 2016; Accepted April 05, 2016; Published April 10, 2016

Citation: Caruso P, Manganotti P, Moretti R (2016) What does Doppler Ultrasonography brings to the diagnosis of Traumatic Vertebral Artery Dissection. J Clin Case Rep 6: 759. doi:10.4172/2165-7920.1000759

Copyright: © 2016 Caruso P, et al. This is an open-access article distributed under the terms of the Creative Commons Attribution License, which permits unrestricted use, distribution, and reproduction in any medium, provided the original author and source are credited.

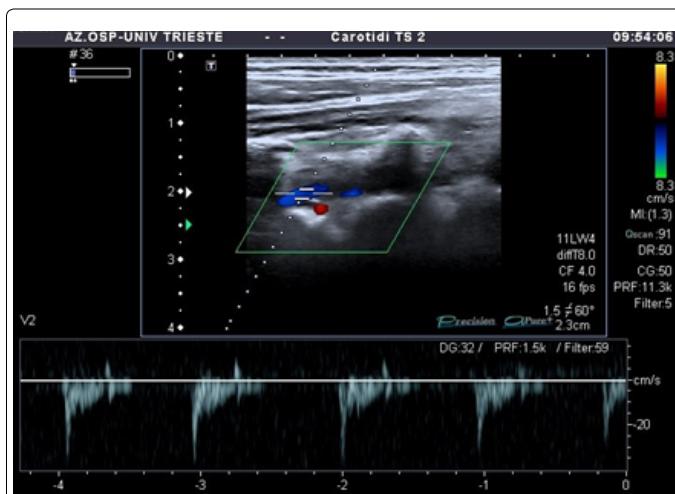


Figure 2: Color-duplex ultrasound, B mode examination, showing left vertebral artery with hypoechoic vessel wall with abnormal flow such as color aliasing, flow demodulated with minor systolic picks (VPS 27 cm/s) and none diastolic picks.

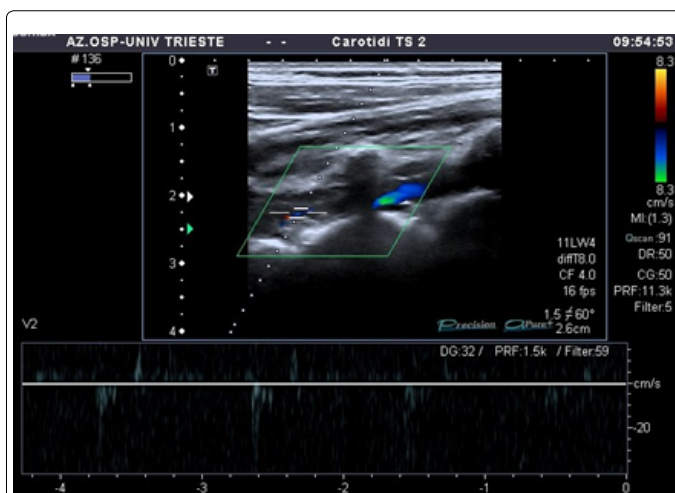


Figure 3: Color-duplex ultrasound, B mode examination, showing left vertebral artery with hypoechoic vessel wall with abnormal flow such as color aliasing, flow demodulated with minor systolic picks (VPS 27 cm/s) and none diastolic picks.

diminishing of pinprick and temperature sensation on the right side of the body and on the left side of the face, she accused diplopia and was still evident left ptosis. T1-weighted magnetic resonance (MR) imaging performed couple of days after presentation revealed a bulbar hypointense signal on the left inferior later part compatible with acute stroke. Angiography MR confirmed left vertebral artery occlusion. Patient then started rehabilitation therapy and symptoms slowly improved. When the patient was discharged one month later, she was doing well, with improving, although not yet normal, sensitivity in her right part of the body and left part of the face. After a couple of months color-duplex ultrasound was performed again. Examination showed partial vessel canalization, with a feeble hemodynamic systolic and diastolic picks signs in the left vertebral artery.

Discussion

Cervical artery dissection has become increasingly recognized as an important cause of posterior circulation stroke in the young. VAD

typically presents with ipsilateral neck or occipital pain preceding a posterior circulation ischemic event. Subsequent neurologic deficits arise either because of ischemia from occlusion or because of distal artery to artery thromboembolism. The etiology of VAD may be either traumatic or spontaneous. The vertebral arteries are sensitive to injury from head or neck torsion because of their anatomy [1]. Data from literature suggest that the annual incidence of spontaneous carotid-artery dissection ranged from 2.5 per 100,000 to 3 per 100,000, while the annual incidence of spontaneous vertebral-artery dissection can be estimated at 1 per 100,000 to 1.5 per 100,000 [2-4]. Spontaneous dissections of the carotid or vertebral artery account for only about 2% of all ischemic strokes. Traumatic dissection occurs in approximately 1% of all patients with blunt injury mechanisms, and is frequently initially unrecognized [5]. Even if dissections are estimated to account for only 2% of all ischemic strokes, the burden of this pathology and the subsequent stroke is still high, especially in young patients, and account for approximately 20% of strokes in patients less than 45 years of age [6]. Traumatic dissection may often occur after motor vehicle accidents or other impact mechanisms that cause rapid deceleration with stretching of the internal carotid artery over the lateral masses of the cervical vertebrae. Similarly might be the consequence of hyperflexion of the neck with compression of the artery between the mandible and cervical spine. Finally excessive rotation, distraction, or flexion-extension injuries of the neck are responsible of vertebral dissections, rarely cerebral angiography or interventional procedures may cause iatrogenic dissections [7]. Arterial dissection can cause ischemic stroke either by thromboemboli forming at the site of injury or as a result of hemodynamic insufficiency due to severe stenosis or occlusion. Advances in imaging techniques have allowed a greater recognition of VAD. Combined MR/TC imaging and MR/TC angiography examination is generally considered to be the best modality for initial evaluation of suspected VAD [8].

Recently published studies underscore the advantages of the MRI fat-suppression technique in the imaging of the thickened vessel wall and intramural hematoma in dissection, particularly in the V3 segment [9-12] MRA is increasingly replacing conventional angiography despite certain limitation, eg, overestimation of the degree of stenosis [13,14]. By using MRA in combination with both hemodynamic and morphological findings revealed in the duplex color-flow evaluation, a reliable diagnosis can be obtained and appropriate treatment with anticoagulants started.

Extracranial vertebral artery (ECVA) dissection has been reported with increasing frequency during the last decade. The most common clinical findings are brain stem or cerebellar ischemic symptoms preceded by severe neck pain and/or incidental headache. Occasional patient have radicular symptoms. Angiography is the current method of choice in the diagnosis of cervical artery dissection, whereby irregular stenosis, double lumen, pseudo-aneurysm formation and tapering or occlusion of the vessel can be shown. Because the investigation of the vertebra-basilar region carries certain risk factors, this procedure is increasingly being replaced by noninvasive techniques. MRI, MRA and Duplex ultrasonography offer potential advantages in the noninvasive assessment of the extracranial vascular disease but their specificity and sensitivity is not very high. According to Duplex ultrasonography, the extracranial portion of the VA can be divided into the following segments: V0, origin; V1 between the origin and the entry into the transverse foramen of the C6 vertebra; V2, midcervical course between processes C6 to C2 vertebrae; and V3, atlas loop region. Color duplex evaluation and spectral analysis were used to assess hemodynamic data from the vessel: flow velocity and direction as well as waveform

characteristics. In the larger study on the topic, where 15 patients have been enrolled [15], a dissection was primarily detected with duplex color-flow imaging. In these patients the interval between the initial clinical symptoms and ultrasound examination was 2-3 days (range 0.5-4). Ultrasonographic abnormalities of VA were, on the other hand, observed in all patients. In 6 patients the artery was injured at the origin. Thickening of the vessel wall and the heterogeneous echogenic structures with irregular surface in the lumen were seen in all patients. In 3 of these patients, the VA was occluded directly at the ostium. More distally, the vessel lumen without detectable blood flow (a very typical sign for occlusion) was recognized. The distal V1 and proximal V2 segments were the most frequent localization of dissection in Bartels patients. The point of entry of the ECVA into the transverse foramen of the C6 vertebra was especially affected (11 dissection). Here a localized increase in the diameter of the artery with thickening of the vessel wall was observed. In some cases, within a thickened irregular vessel wall an echolucent intramural hematoma or different intravascular echoes were present. In 2 patients, an intimal flap or a dissecting membrane with true and false lumen underscored the diagnosis. A tapering stenosis (in 3 subjects with distal occlusion) was a very common finding (n°10). Furthermore, variable Doppler spectral waveforms such as biphasic patterns, resistive patterns and decreased systolic and diastolic flow velocities were observed. Dissection in the V3 segment (n°1) could not be detected directly on the B-scan. The diagnosis was based on indirect signs such as a high-resistance flow pattern with increased pulsatility index and decreased diastolic flow (or even absent diastolic flow component) within normally configured arteries in the V1 and V2 segments.

Color-Doppler sonography, which is a non-invasive and cost-effective method, is a suitable screening test for vertebral artery stenosis and dissection [15-17]. However, very few studies have been performed to determine Doppler criteria for identifying proximal vertebral artery stenosis [18,19]. The sensitivity for detecting extracranial vertebral artery dissection was estimated around 75% in literature. Anyway the distal V2 and V3 segments cannot always be satisfactorily imaged; therefore, diagnosis is based on indirect hemodynamic signs [20-23]. Whereas angiography only shows an alteration of the vessel lumen, duplex color-flow imaging provides additional information about the hemodynamic parameters and the pathology of the vessel wall. Because duplex color-flow imaging can be repeated as often as necessary, it is a proven technique for early diagnosis, follow-up examination, and accordingly, therapeutic decisions (i.e. the duration of anticoagulant treatment). The ultrasonographic abnormalities varied on the basis of the mechanism of the dissection and pathological anatomy. Usually in a dissection, after the primary tear of the intima, blood flow into the arterial wall between the intima and media, causing an intramural hematoma and a thickening of the vessel wall. Subintimal hematoma can produce various degrees of stenosis, subadventitial hemorrhage can cause a pseudoaneurysm. Rupture back into the lumen can result in a false lumen. Accordingly, the ultrasonographic findings varied from minor lesion (irregularities and thickening of the vessel wall with intramural hematoma and/or narrowing of the lumen without hemodynamic alteration) to major structural lesion such as severe stenosis or occlusion. Regarding localization, in our patient the most common site of dissection was the distal V1 segment, especially at the point of the entry into the transverse foramen of C6 vertebra. This midvertebral region is possibly one of the most vulnerable spots, where the artery is exposed to the greatest mechanical injury. Particularly in this area, we were able to image the major pathological findings in the vessel wall, such as an intramural hematoma, intimal flap with a true

and false lumen, localized decrease in the diameter of the artery or an irregular stenosis. Compared with the other segment of the VA, the midcervical course is the easiest to examine because of clear anatomic condition (straight course of the artery, interrupted by the transverse processes of the vertebrae). Additionally, before the entry of the VA in the transverse foramen of the C6 vertebra, insonation along an extended vessel segment (without acoustic shadowing of the vertebra) is possible, so that alteration of the vessel wall and an irregular stenosis can be well recognized. In this region follow-up examinations are most reliable, since the transducer position for the imaging of the midcervical course is relatively constant (Bartels). The distal V2 and V3 segments cannot always be satisfactorily imaged; therefore diagnosis is based on indirect hemodynamic signs. In patients with a typical history and clinical symptoms related to the vertebra-basilar territory, decreased diastolic flow velocity or a missing diastolic component in the spectral analysis, registered in the midcervical course of the affected artery, is very suspicious for a more distal dissection. However, the presence of these high-resistance flow patterns is not specific, since this may also occur in stenosis or occlusion of any etiology. Diagnostic errors also can be made in the case of hypoplastic VA, particularly if it ends in the posterior inferior cerebellar artery. In this relatively common anatomic variation, a Doppler spectrum similar to that of an intracranial obstruction of the VA can be found. For this reason a measurement of the VA diameter of both sides is mandatory. Different spectral analysis in arteries of equal width mostly indicates VA pathology.

In the clinical practice more often vertebral artery dissection is an elusive diagnosis, because of different nonspecific presentations with atypical clinical symptoms, and varied symptomatology depending on where along the vertebral artery a dissection occurs [24]. Generally dizziness or vertigo are the most common symptom among individuals with vertebral artery dissection, data from literature show almost in 58% of VAD patients, then headache (51%), neck pain (46%). More specific neurologic symptoms are gait problems or ataxia, nausea/vomiting, and visual symptoms, nystagmus, dysphagia, and tinnitus. In Conclusion, we report a case of traumatic vertebral dissection in a young woman after a minor cervical trauma by distraction after car accident. The case emphasizes the importance of considering dissection early on in any young patient with neck pain or stroke-like symptoms particularly after car accident or even smaller trauma. The physiopathology of posterior circulation in these cases in light of the damage mechanism in these type of mild trauma. Combined Doppler ultrasound and TC imaging and TC angiography is the best modality for initial evaluation in order to rapidly start the anticoagulation treatment. Therefore, we hypothesize a more specific employment of ultrasonographic approach to earlier diagnosis of VA dissection. It can be helpful to employ directly in bedridden patients, quite often due to a dissection, vomit, nausea and imbalance, and its rather costless in comparison to CT or MRI angiography.

References

1. Desouza RM, Crocker MJ, Haliasos N, Rennie A, Saxena A (2011) Blunt traumatic vertebral artery injury: a clinical review. *Eur Spine J* 20: 1405-1416.
2. Schievink WI, Mokri B, O'Fallon WM (1994) Recurrent spontaneous cervical-artery dissection. *N Engl J Med* 330: 393-397.
3. Schievink WI (2001) Spontaneous dissection of the carotid and vertebral arteries. *N Engl J Med* 344: 898-906.
4. Gottesman RF, Sharma P, Robinson KA, Arnan M, Tsui M, et al. (2012) Clinical Characteristics of Symptomatic Vertebral Artery Dissection. A Systematic Review. *Neurologist* 18: 245-254.
5. Kim YK, Schulman S (2009) Cervical artery dissection: pathology, epidemiology and management. *Thromb Res* 123: 810-821.

6. Bogousslavsky J, Regli F (1987) Ischemic stroke in adults younger than 30 years of age. Cause and prognosis. *Arch Neurol* 44: 479-482.
7. Tramo MJ, Hainline B, Petito F, Lee B, Caronna J (1985) Vertebral artery injury and cerebellar stroke while swimming: case report. *Stroke* 16: 1039-1042.
8. Malhotra AK, Camacho M, Ivatury RR, Davis IC, Komorowski DJ, et al. (2007) Computed tomographic angiography for the diagnosis of blunt carotid/vertebral artery injury: a note of caution. *Ann Surg* 246: 632-642.
9. Sturzenegger M, Mattle HP, Rivoir A, Rihs F, Schmid C (1993) Ultrasound findings in spontaneous extracranial vertebral artery dissection. *Stroke* 24: 1910-1921.
10. Sturzenegger M (1995) Spontaneous internal carotid artery dissection: early diagnosis and management in 44 patients. *J Neurol* 242: 231-238.
11. Zuber M, Meary E, Meder JF, Mas JL (1994) Magnetic resonance imaging and dynamic CT scan in cervical artery dissections. *Stroke* 25: 576-581.
12. Walz ET (1993) Magnetic resonance imaging in the diagnosis of vertebral artery dissection. *J Neuroimaging* 3: 61-93.
13. Rother J, Schwartz A, Wentz KU, Rautenberg W, Hennerici M (1994) Middle cerebral artery stenosis: assessment by magnetic resonance angiography and transcranial dopplerultrasound. *Cerebrovasc Dis.* 4: 273-279.
14. Nguyen Bui L, Brant-Zawadzki M, Verghese P, Gillan G (1993) Magnetic resonance angiography of cervicocranial dissection. *Stroke* 24: 126-131.
15. Bartels E, Flügel KA (1996) Evaluation of extracranial vertebral artery dissection with duplex color-flow imaging. *Stroke* 27: 290-295.
16. Clevert DA, Jung EM, Johnson T, Kubale R, Rupp N, et al. (2007) Cervical artery dissection: improved diagnosis by B-Flow ultrasound. *Clin Hemorheol Microcirc* 36: 141-153.
17. Gottesman RF, Sharma P, Robinson KA, Arnan M, Tsui M, et al. (2012) Imaging Characteristics of Symptomatic Vertebral Artery Dissection: A Systematic Review. *Neurologist* 18: 255-260.
18. Mutze S, Rademacher G, Matthes G, Hosten N, Stengel D (2005) Blunt cerebrovascular injury in patients with blunt multiple trauma: diagnostic accuracy of duplex Doppler US and early CT angiography. *Radiology* 237: 884-892.
19. Clevert DA, Rupp N, Reiser M, Jung EM (2005) Improved diagnosis of vascular dissection by ultrasound B-flow: a comparison with color-coded Doppler and power Doppler sonography. *Eur Radiol* 15: 342-347.
20. Herrera DA, Vargas SA, Dublin AB (2008) Endovascular treatment of traumatic injuries of the vertebral artery. *AJNR Am J Neuroradiol* 29: 1585-1589.
21. Wang H, Orbach DB (2008) Traumatic dissecting aneurysm at the vertebrobasilar junction in a 3-month-old infant: evaluation and treatment strategies. Case report. *J Neurosurg Pediatr* 1: 415-419.
22. Pugliese F, Crusco F, Cardaioli G, Tambasco N, Boranga B, et al. (2007) CT angiography versus colour-Doppler US in acute dissection of the vertebral artery. *Radiol Med* 112: 435-443.
23. Ahn JY, Han IB, Kim TG, Yoon PH, Lee YJ, et al. (2006) Endovascular treatment of intracranial vertebral artery dissections with stent placement or stent-assisted coiling. *AJNR Am J Neuroradiol* 27: 1514-1520.
24. Meier DE, Brink BE, Fry WJ (1981) Vertebral artery trauma: acute recognition and treatment. *Arch Surg* 116: 236-239.